Tiges de croissance dans la chirurgie de la scoliose de l’enfant

Ibrahim Obeid, Jean-Marc Vital

Bordeaux

Scoliose de l'enfant en bas âge et de l'adolescent: 2 problématiques distinctes

- Petit enfant:
  - Développement pulmonaire
  - Risque neurologique

- Grand enfant:
  - Déformation physique
  - Gêne fonctionnelle

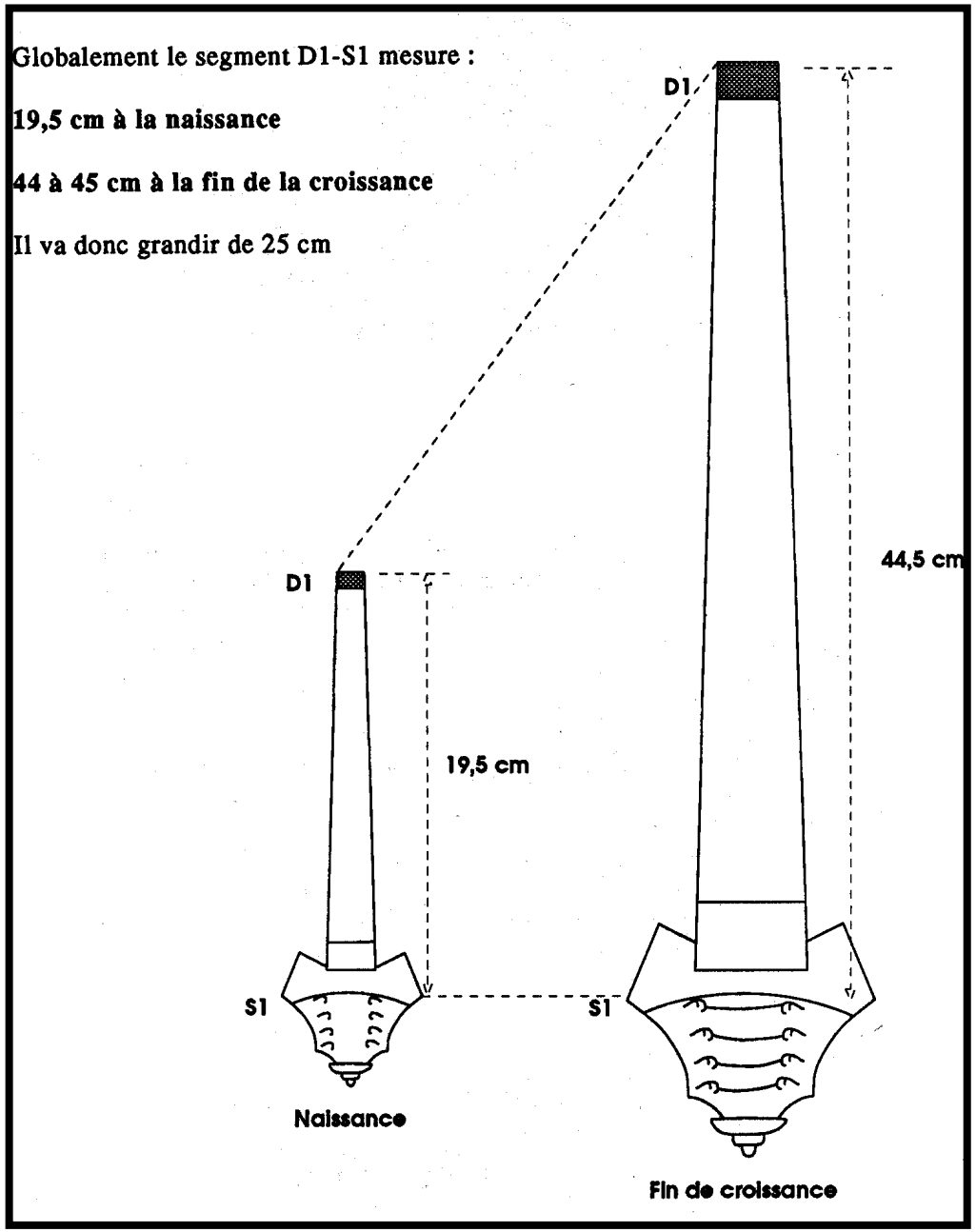

Spinal Growth

Alain Dimeglio

- **From birth to 5**

- Sitting heigth increase : 28 cm G, 29 cm B

- T1-S1 : **10** cm

From 5 to puberty

- T1-S1 : about **1.1** cm/year

- Puberty peak



R.B Winter rule of thumb for growth

- 0.07cm / year /vertebra
- Single Vertebra+disc :

Thoracic : 2.5% of sitting eight
Lumbar : 3.5% of sitting eight

- *E.g.* : 60 º curve at 5 years of age

Anterior and Post spine fusion on 11 segments (T4- L2)

0.07x 11x 11=

8.47 cm of loss of height

Thoracic insufficiency syndrom

Inability for the thorax to support normal respiration or lung growth

Campbell 2001<<<<<

VC < 50% Life span : 45y

❖ **Thoracic segment > 18 cm**

Alveolis number At birth: 50 millions
At 5. years 200 Millions

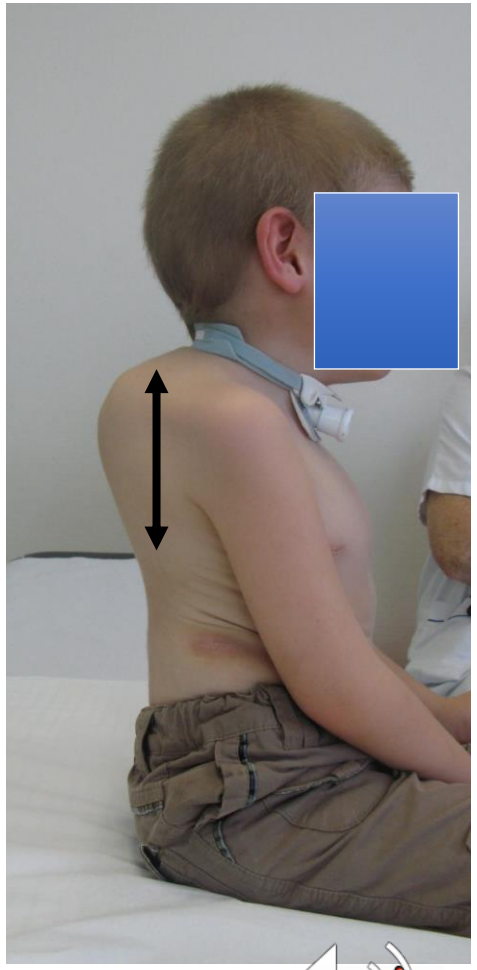

Deformity consequences

- **Volume diminution +++**

Tracheo bronchial compression

Atelectasia (convex side)

- **Lost of diaphragma strength (concavity et convexity)**

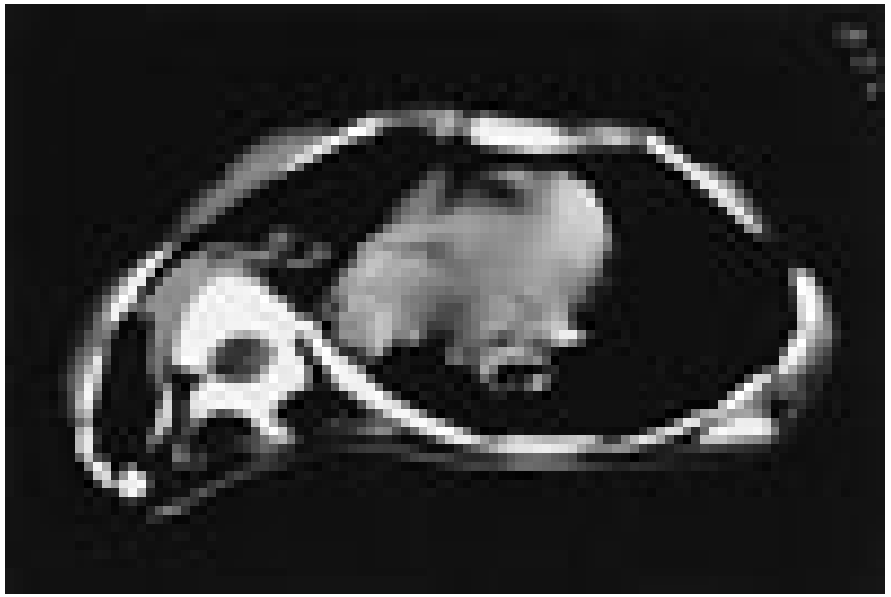

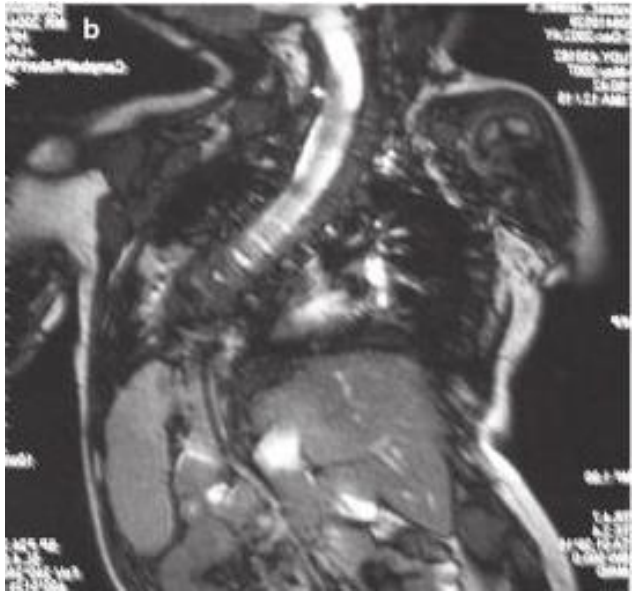

Scoliose du grand enfant (adolescent)

- La croissance rachidienne résiduelle est faible après Risser 1
- Chirurgie définitive de correction arthrodèse par voie postérieure ou antérieure
  - Efficacité prouvée sur le long terme
  - Conservation de la mobilité lombaire

- Chirurgie par VBT ou ligamentoplastie antérieure
  - Toujours en évaluation depuis 10ans
  - Risque de reprise de 30%
  - Préserve la mobilité à court terme
  - Limite entre Indication/contre indication très étroite

Harrington

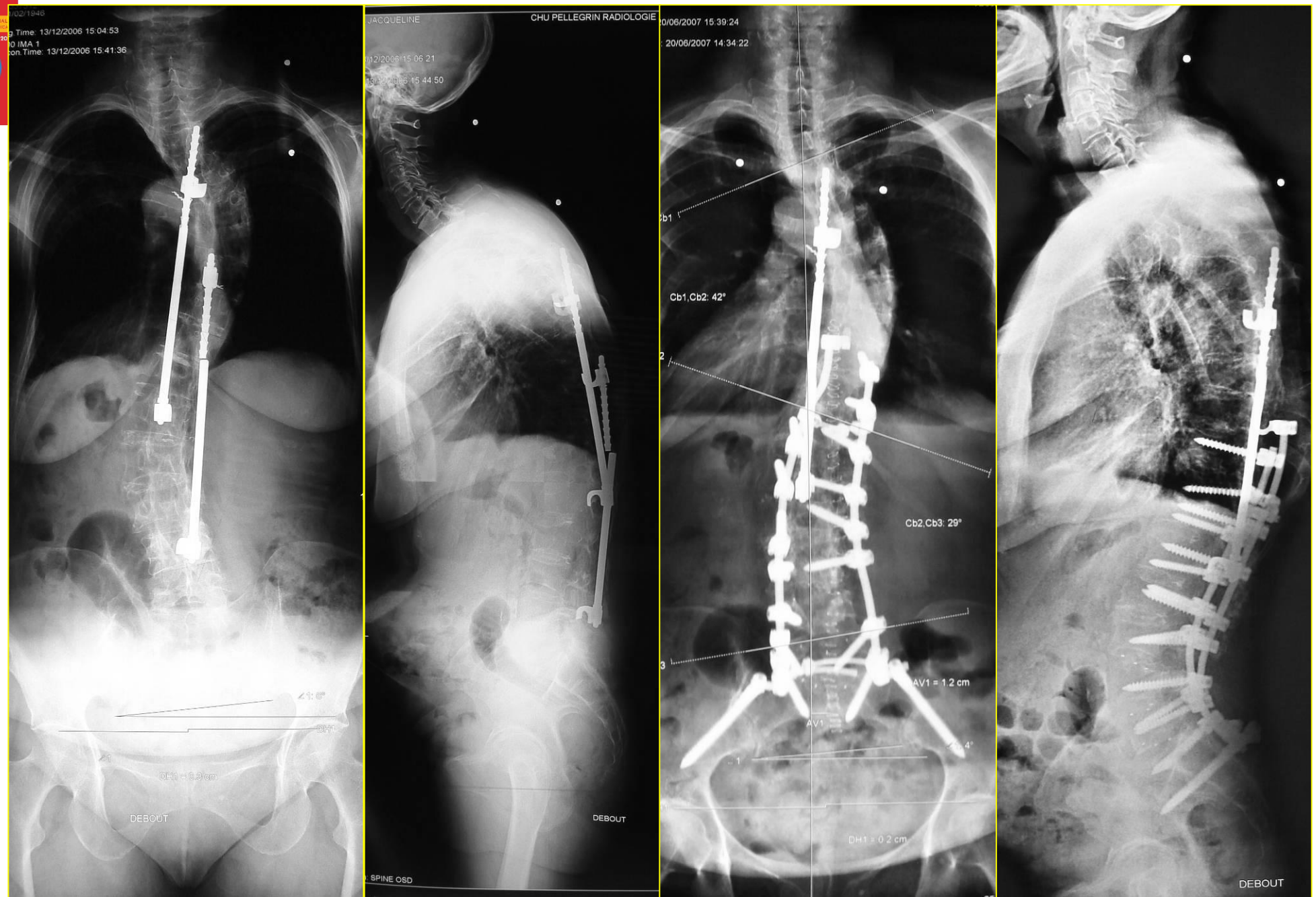
Time: 13/12/2006 15:04:53
con.Time: 13/12/2006 15:41:36
DEBOUT
JACQUELINE
CHU PELLEGRIN RADIOLOGIE
DEBOUT
SPINE OSD
20/06/2007 15:39:24
20/06/2007 14:34:22
Cb1,Cb2: 42°
Cb2,Cb3: 29°
AV1 = 1.2 cm
DH1 = 0.2 cm
DEBOUT

Luque: IMC

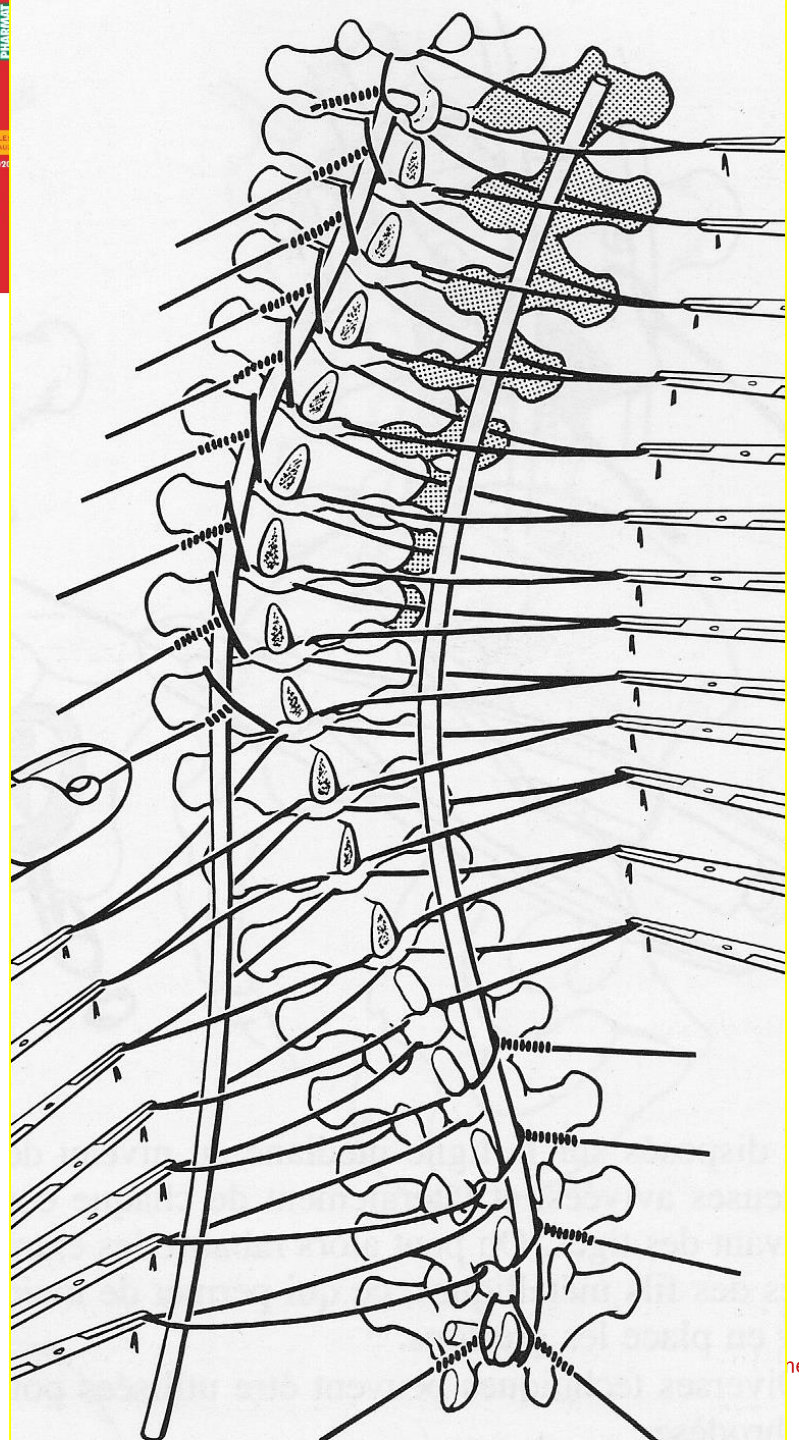

CROCHETS

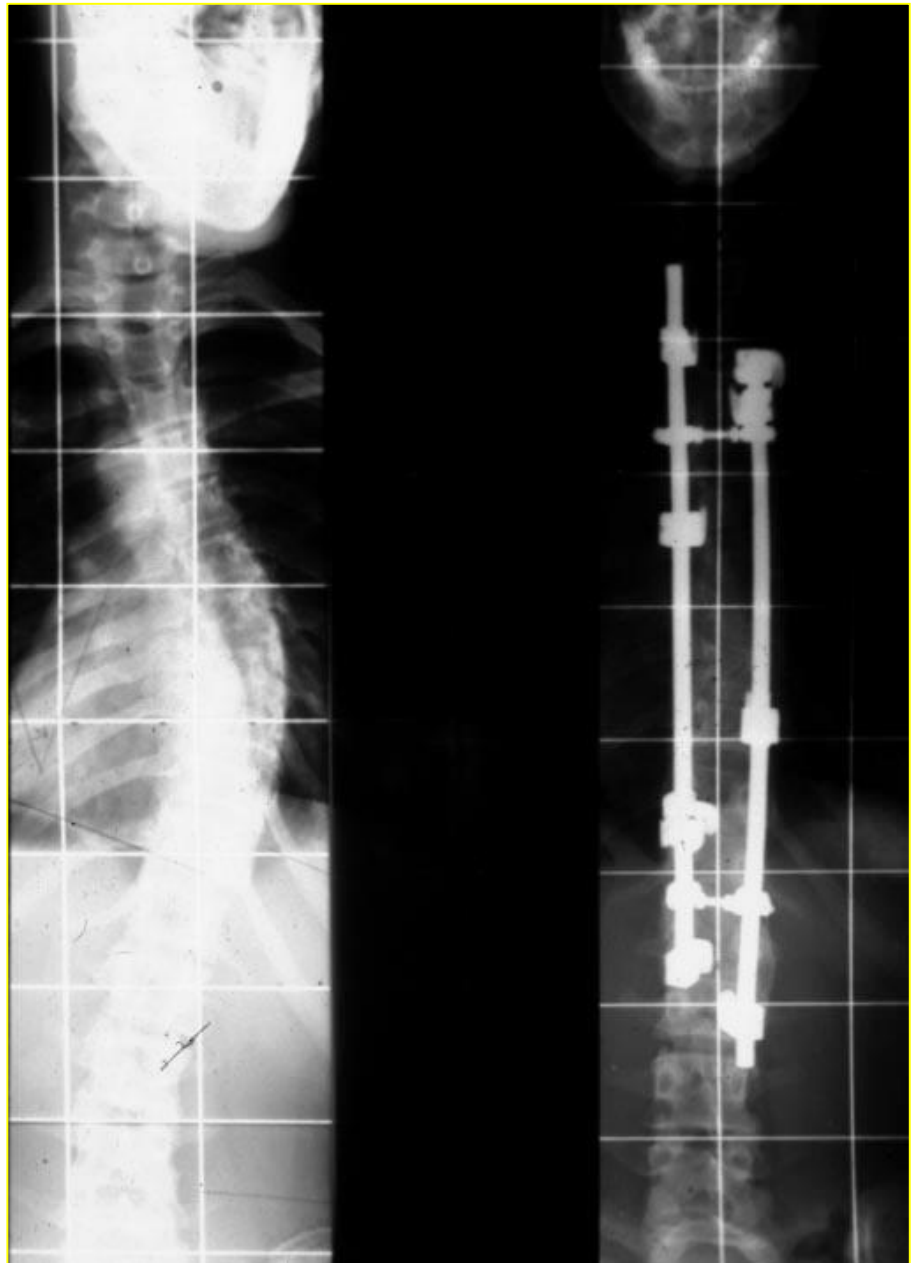

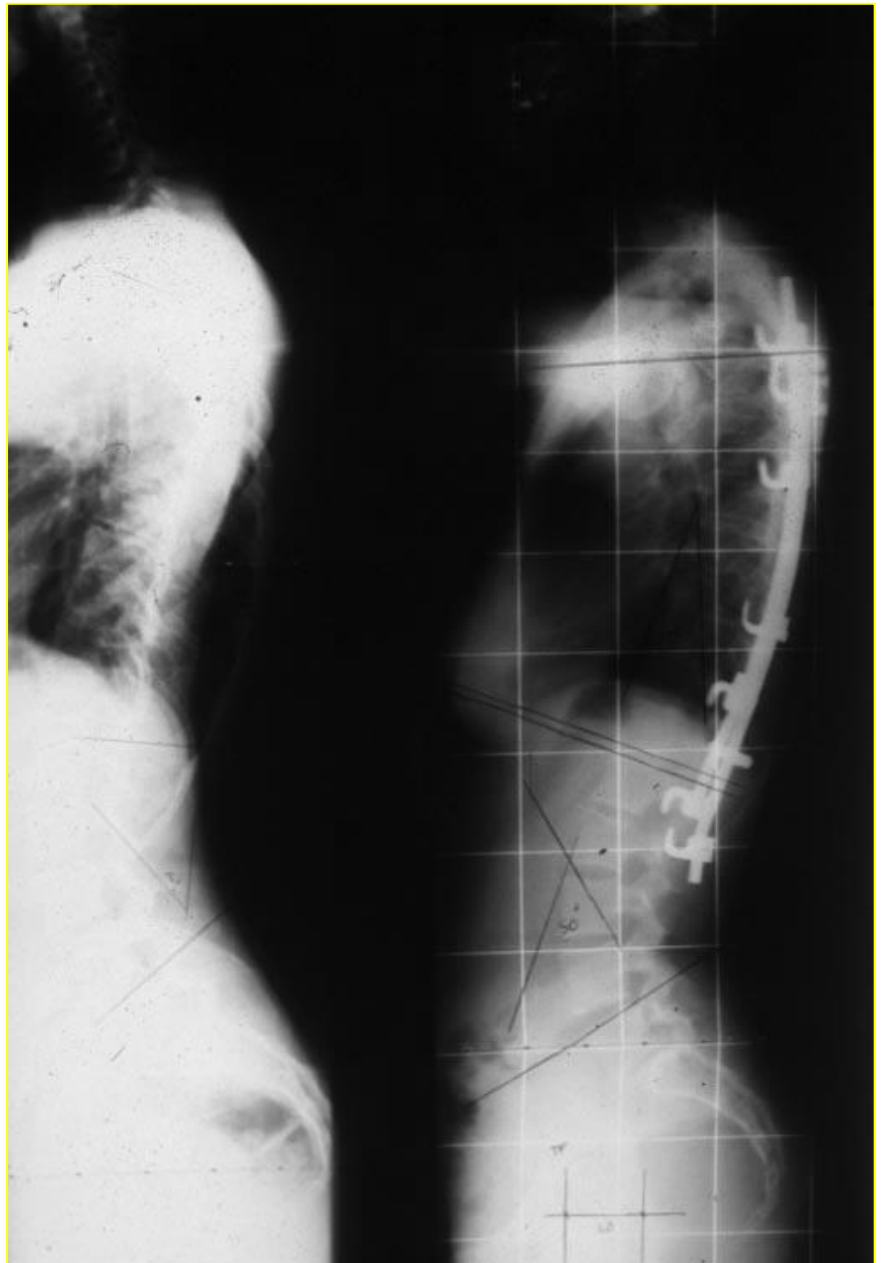

Vis pédiculaires

- Avantage:
  - Fixation très solide des 3 colonnes
  - Excellente correction des courbures même raides
  - Bonne correction de la gibbosité clinique
  - Faible risque neurologique

- Inconvénient: courbe d’apprentissage

VCM et DVR

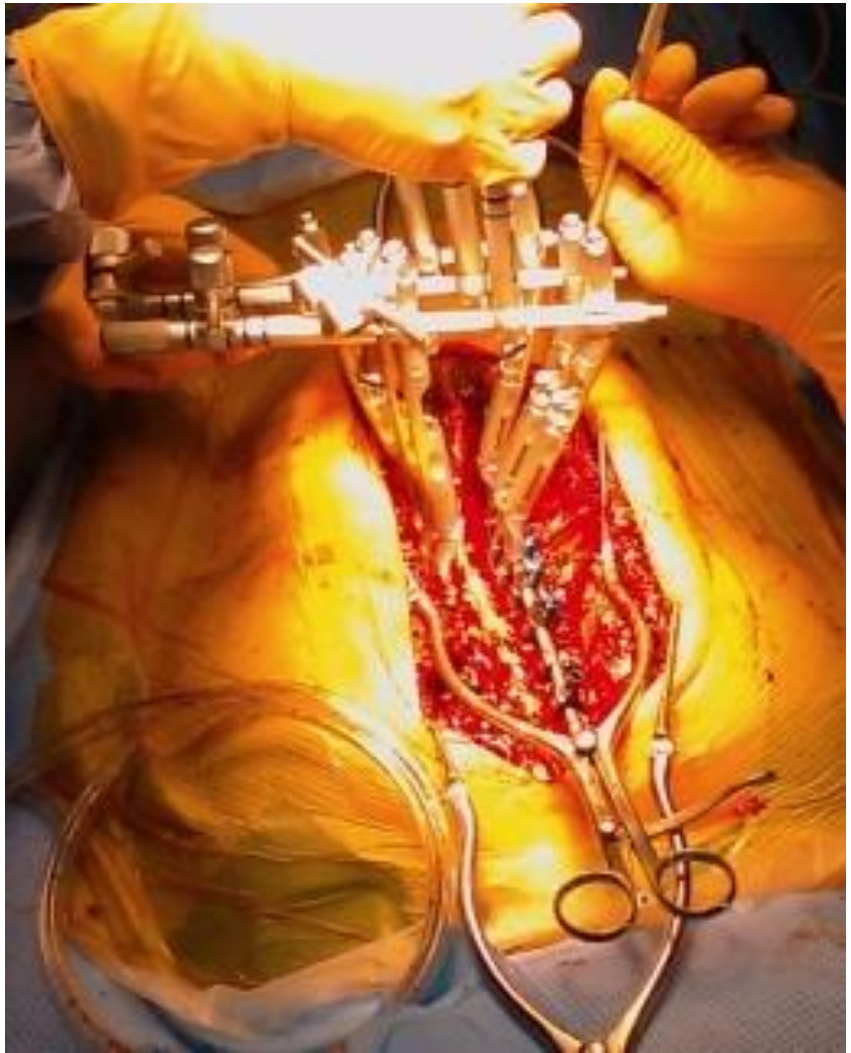

VCM

Preoporative
Postoporative
biospace med

Preoporative
Postoporative
biospace med

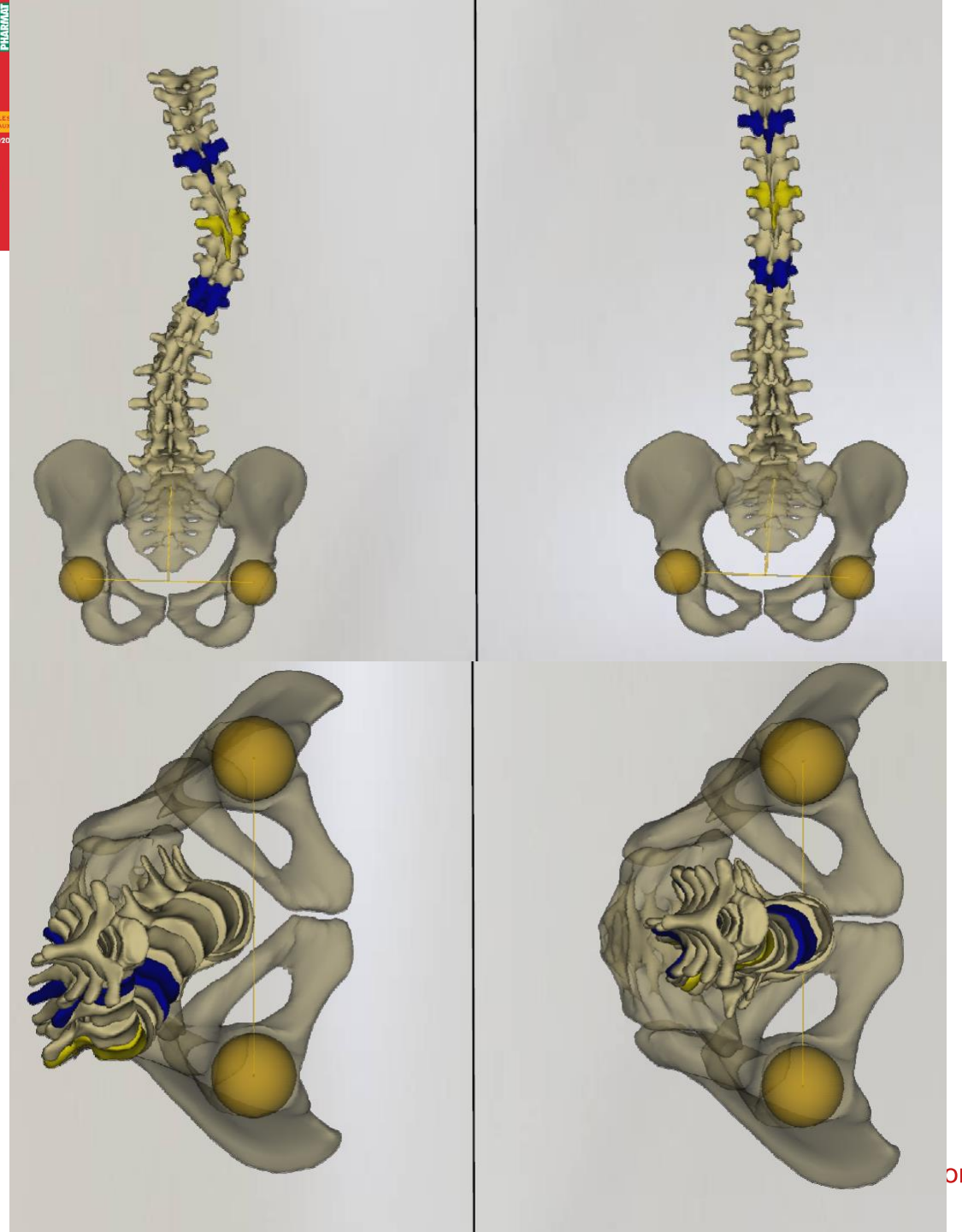

EOS

Correction de la rotation dans le plan Axial amélioration nette de la gibbosité

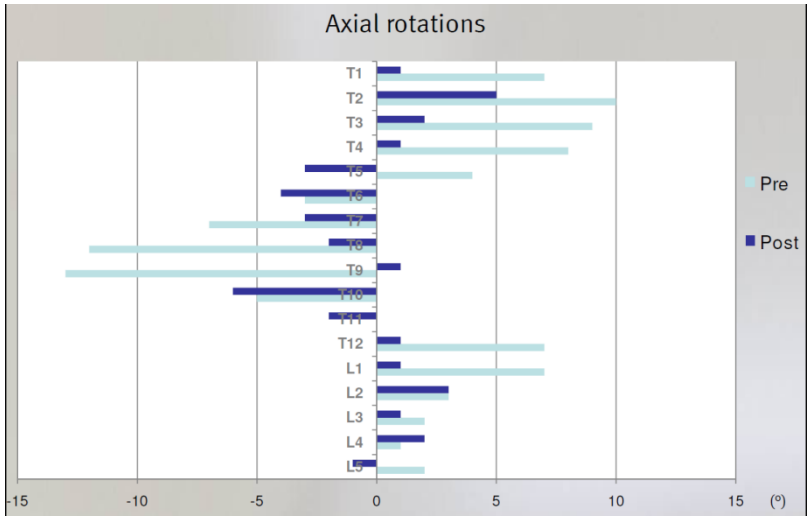

Pas de gibbectomie

AV1 = 2.4 cm
DH1 = 0.1 cm
DH1
DEBOUT

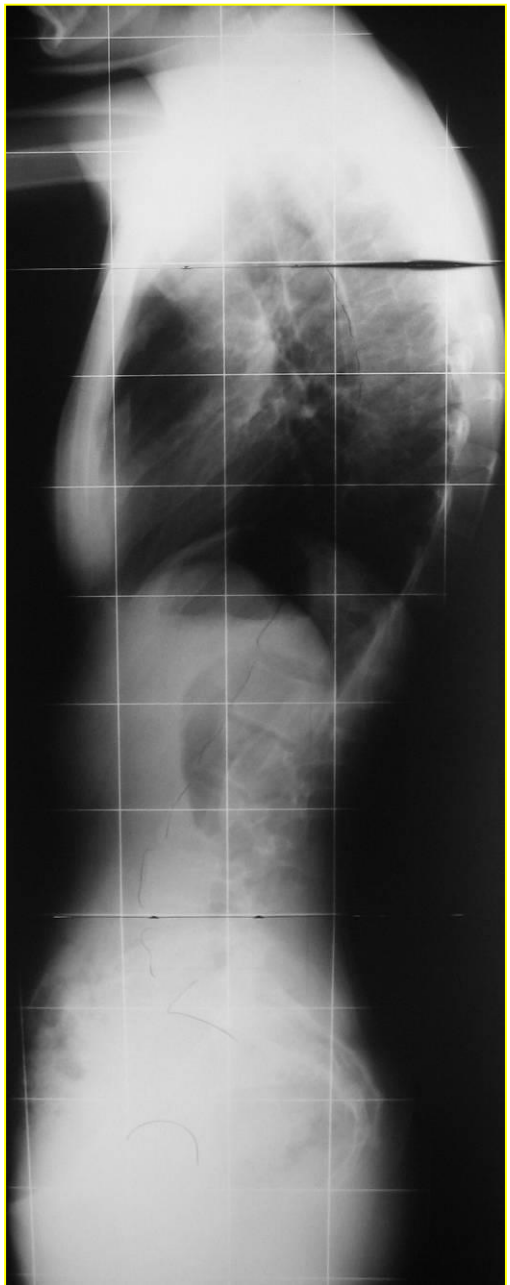

ADET, EDWIGE
1991
Hopital Pelle
LEONAR
Time: 24/10/2005 09:49:46
Time: 25/10/2005 11:46:25
DH1 = 0.3 cm
DEBOUT

/10/2005 09:52:21
25/10/2005 09:50:57
∠5/4: 37°
L4
L3
∠2/3: 46°
L2
DEBOUT

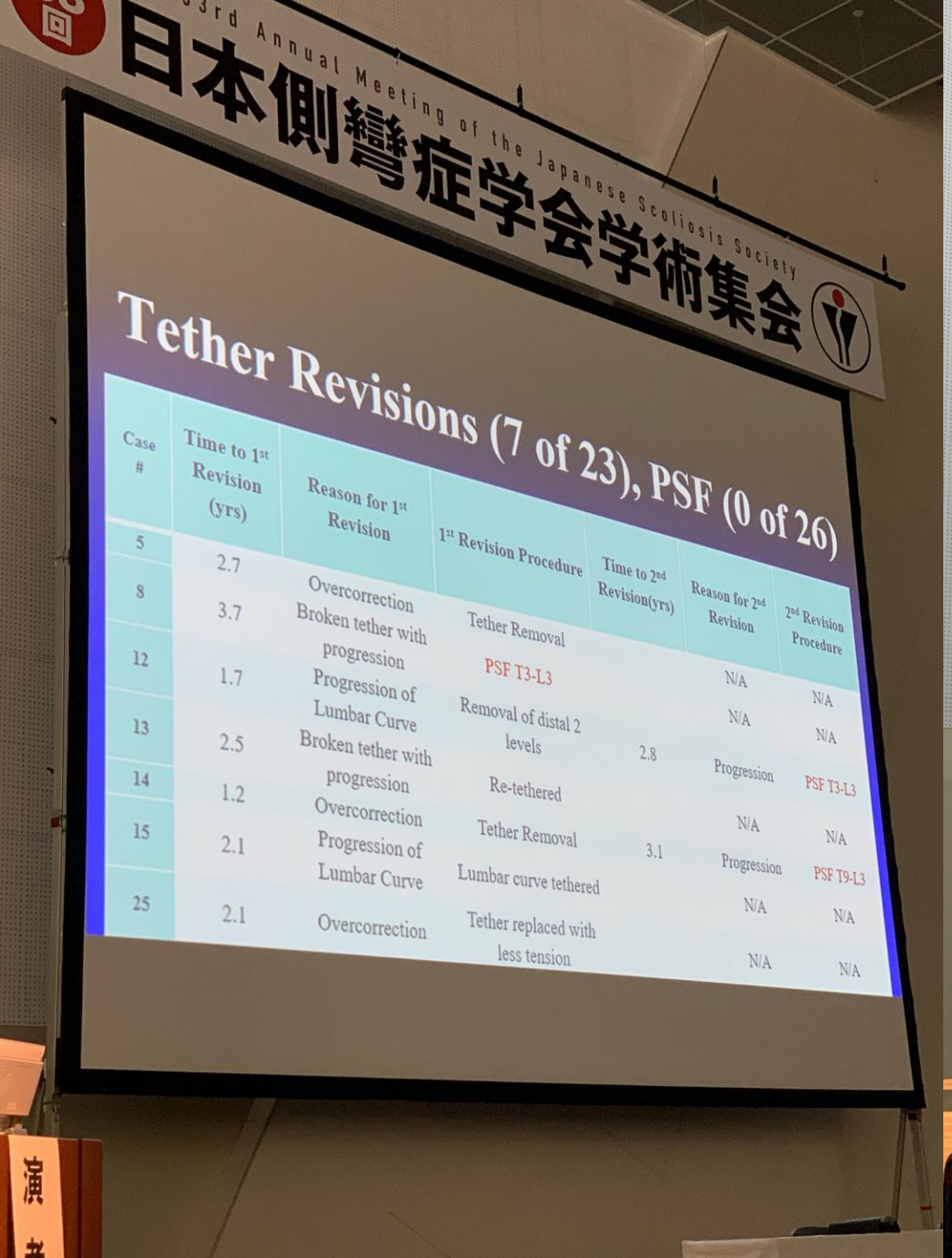

Case #	Time to 1st Revision (yrs)	Reason for 1st Revision	1st Revision Procedure	Time to 2nd Revision(yrs)	Reason for 2nd Revision	2nd Revision Procedure
5	2.7	Overcorrection	Tether Removal		N/A	N/A
8	3.7	Broken tether with progression	PSF T3-L3		N/A	N/A
12	1.7	Progression of Lumbar Curve	Removal of distal 2 levels	2.8	Progression	PSF T3-L3
13	2.5	Broken tether with progression	Re-tethered		N/A	N/A
14	1.2	Overcorrection	Tether Removal	3.1	Progression	PSF T9-L3
15	2.1	Progression of Lumbar Curve	Lumbar curve tethered		N/A	N/A
25	2.1	Overcorrection	Tether replaced with less tension		N/A	N/A

Peter Newton

Scoliose du petit enfant 2 cas de figure et deux possibilités stratégiques

- Arrêter la croissance
- Accompagner la croissance

- Anomalie localisée: traitement localisé et « définitif »
- Anomalie ou courbure étendues: Tiges de croissance

Résection d’une hémi-vertèbre

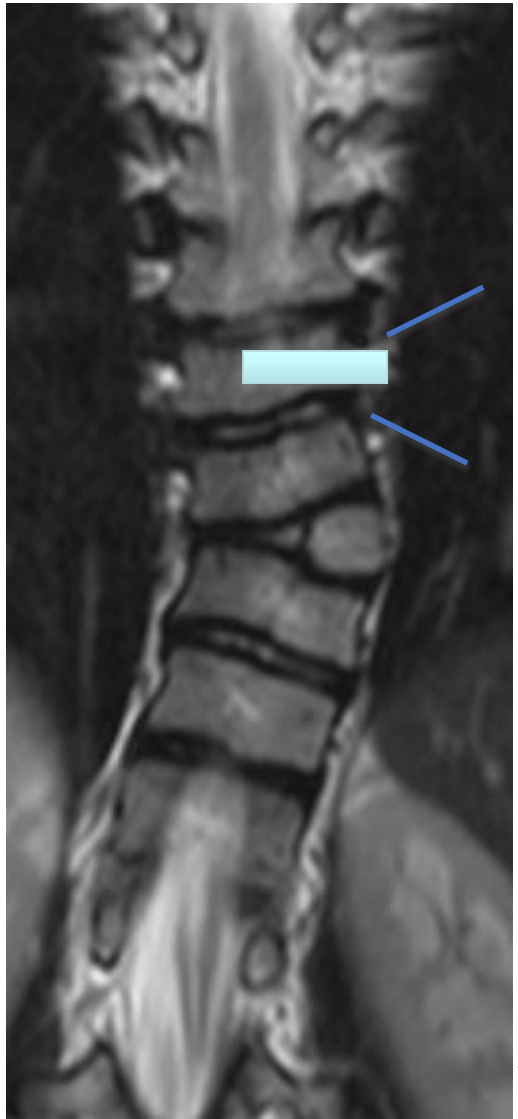

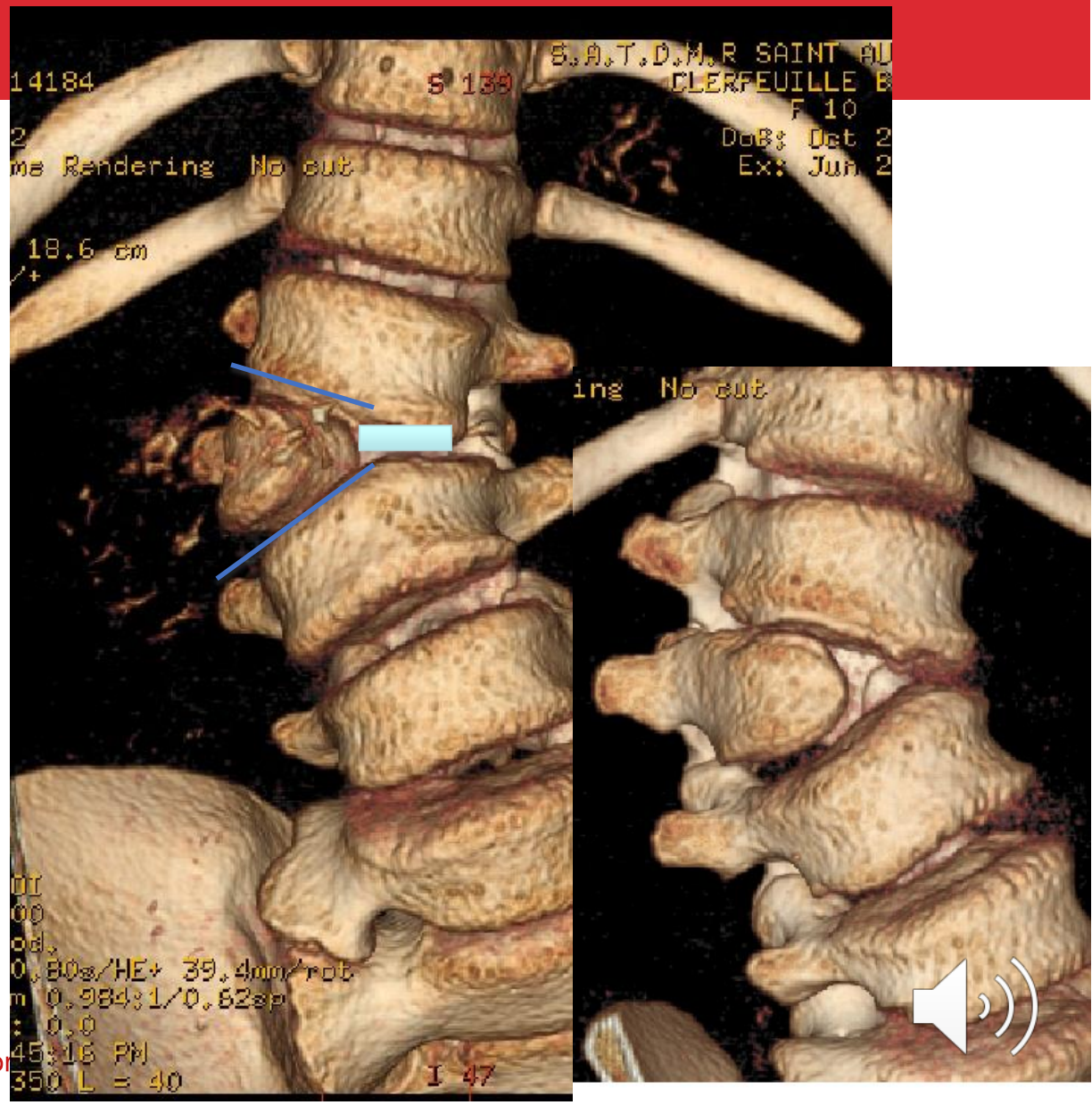

NEUROMONITORING
AVOID EXTENDED APPROACH

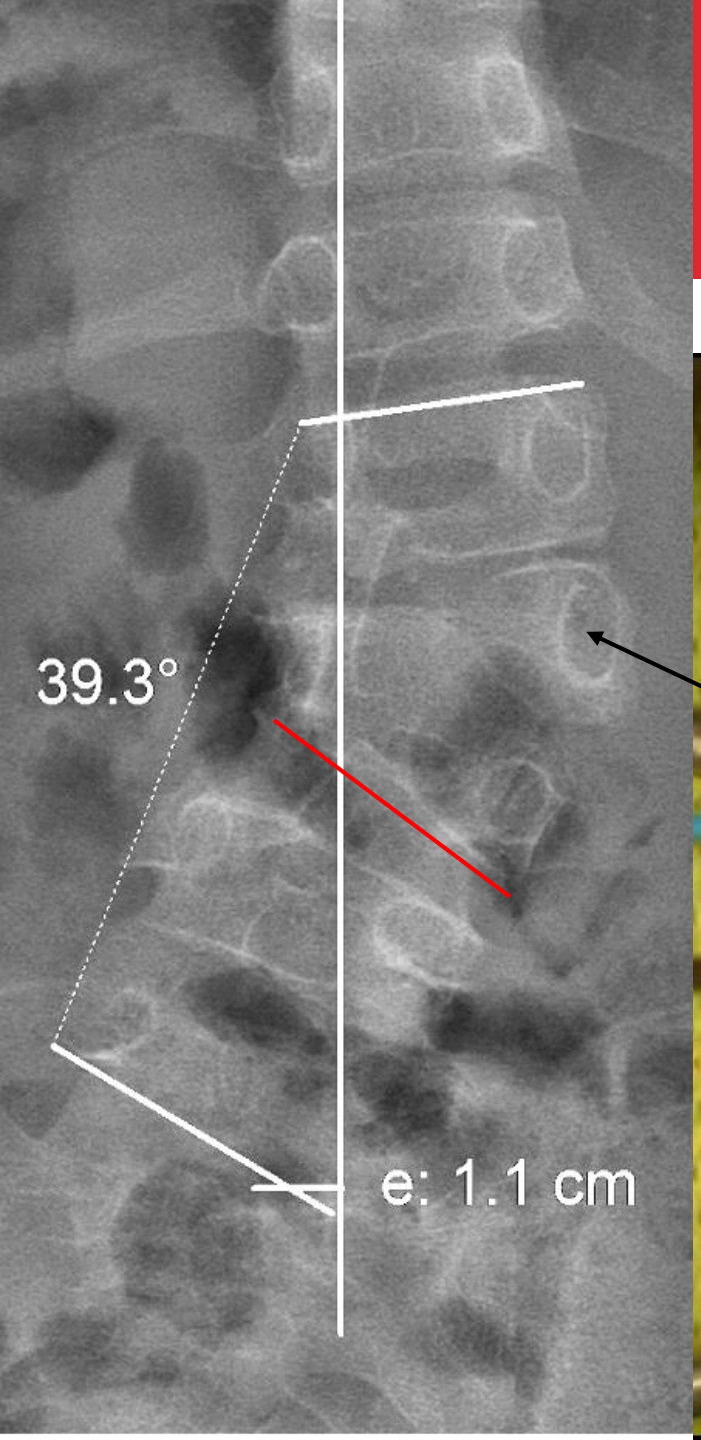

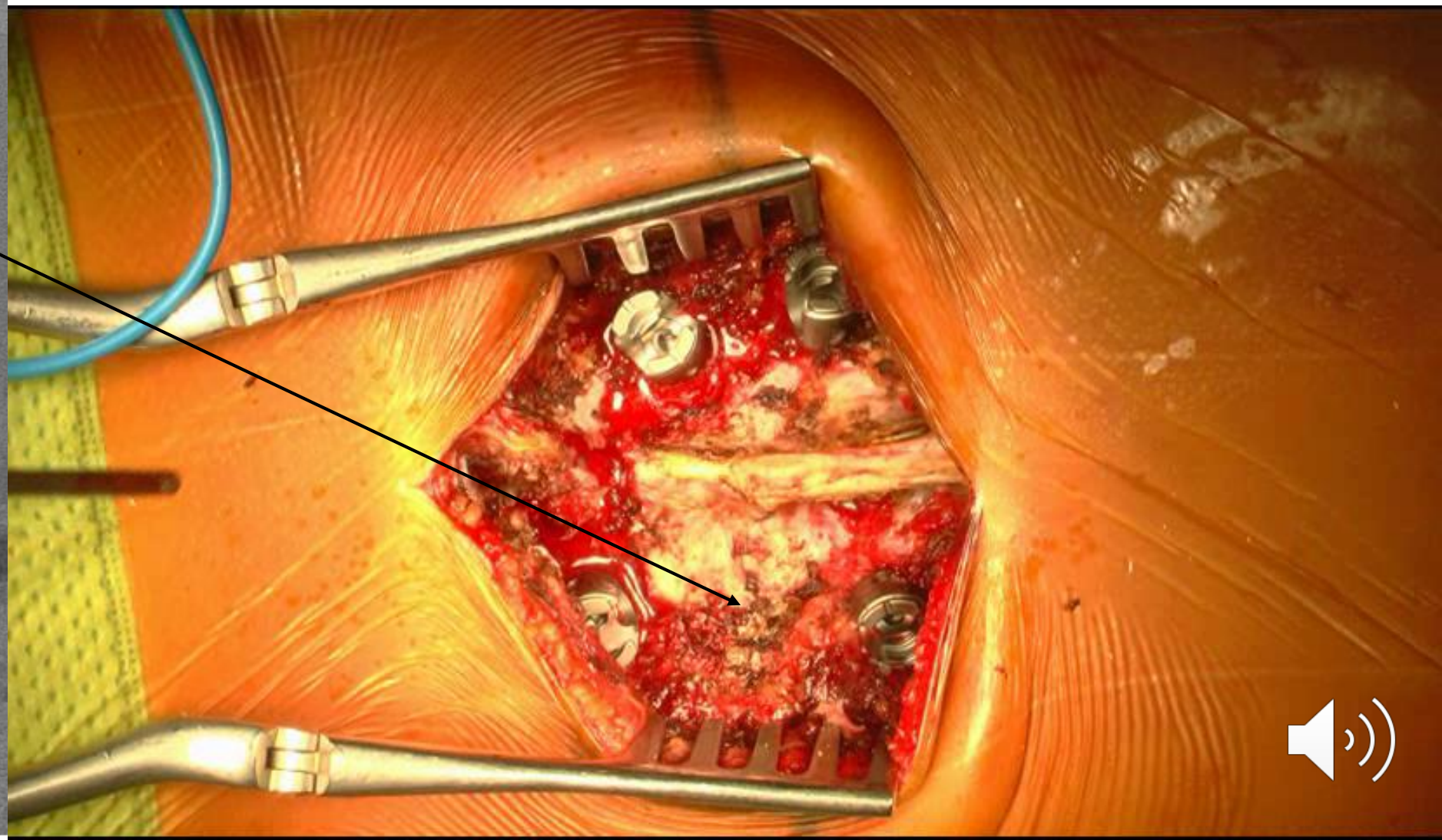

COMPLETE BONE AND CARTILAGE RESECTION
CONCAVE SIDE DISC REMOVAL BY CONVEXE SIDE

COMPLETE CORRECTION OF THE DEFORMITY
4 POINTS CLOSURE

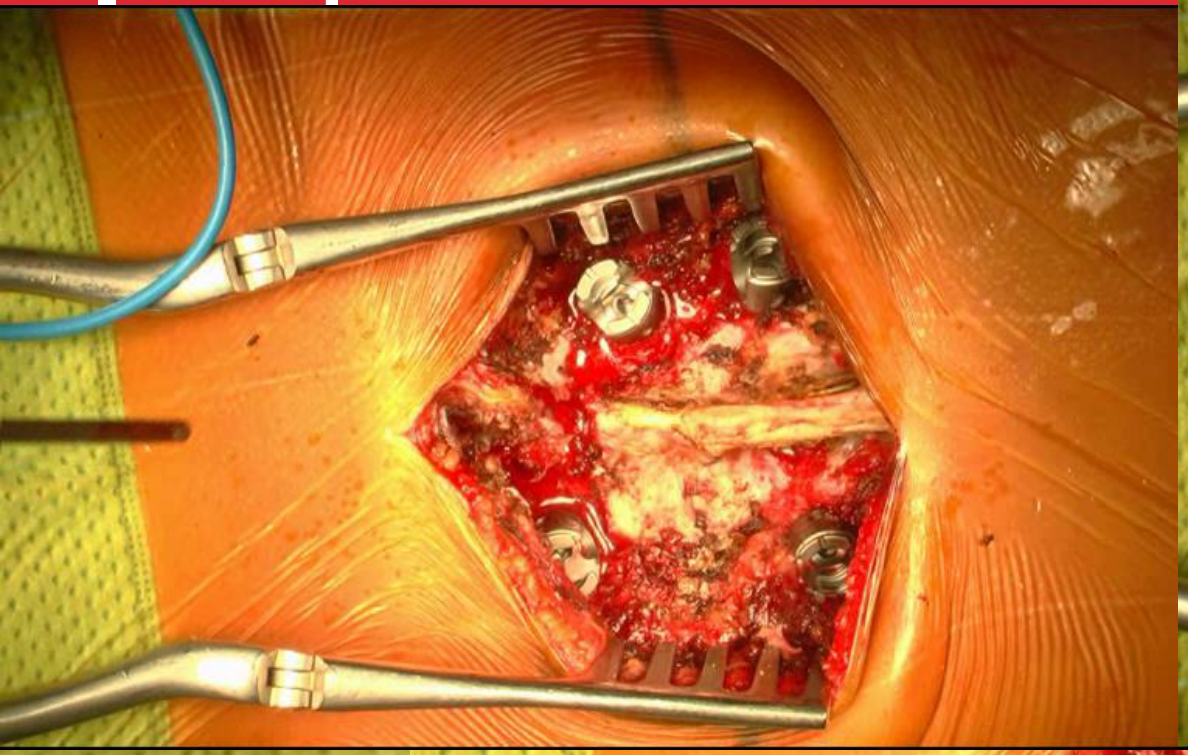

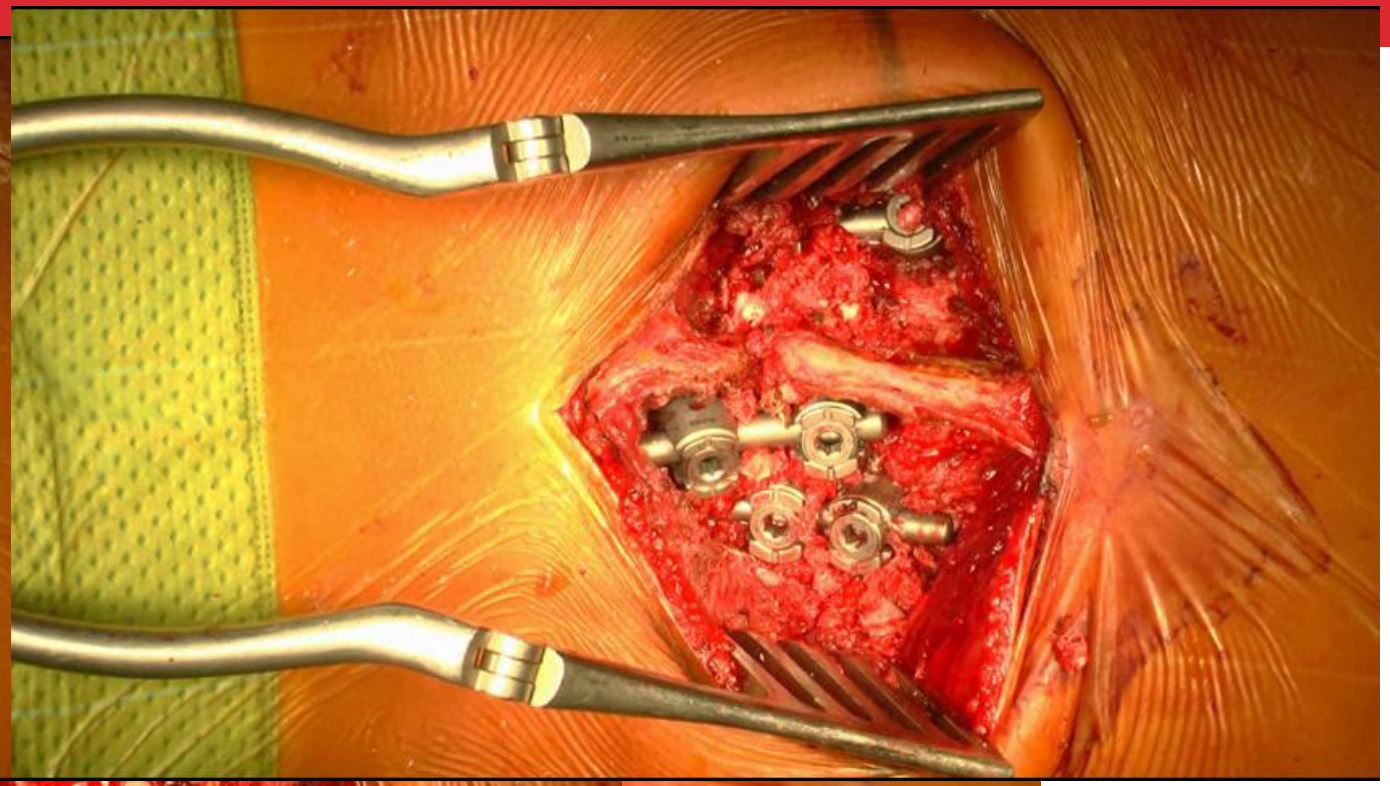

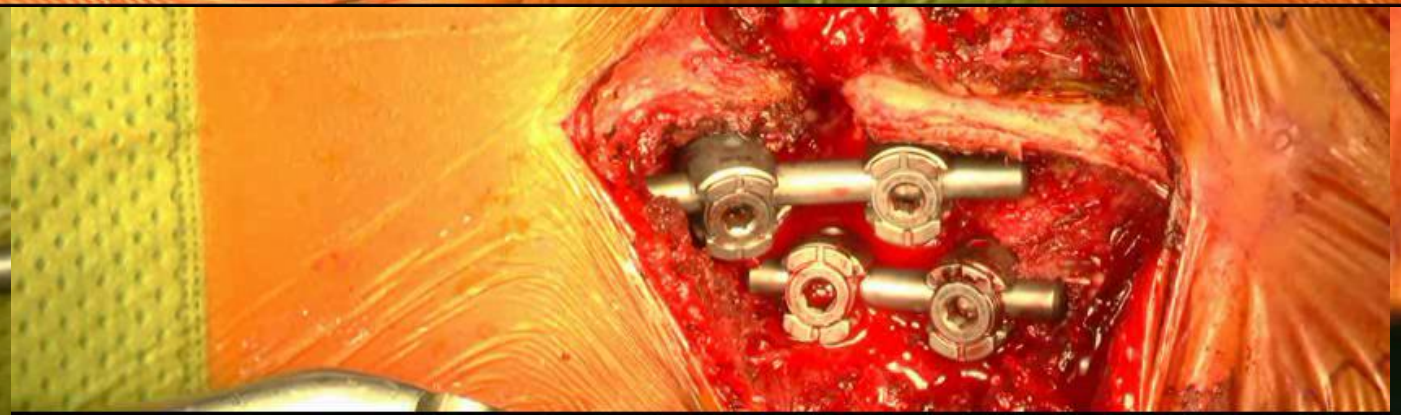

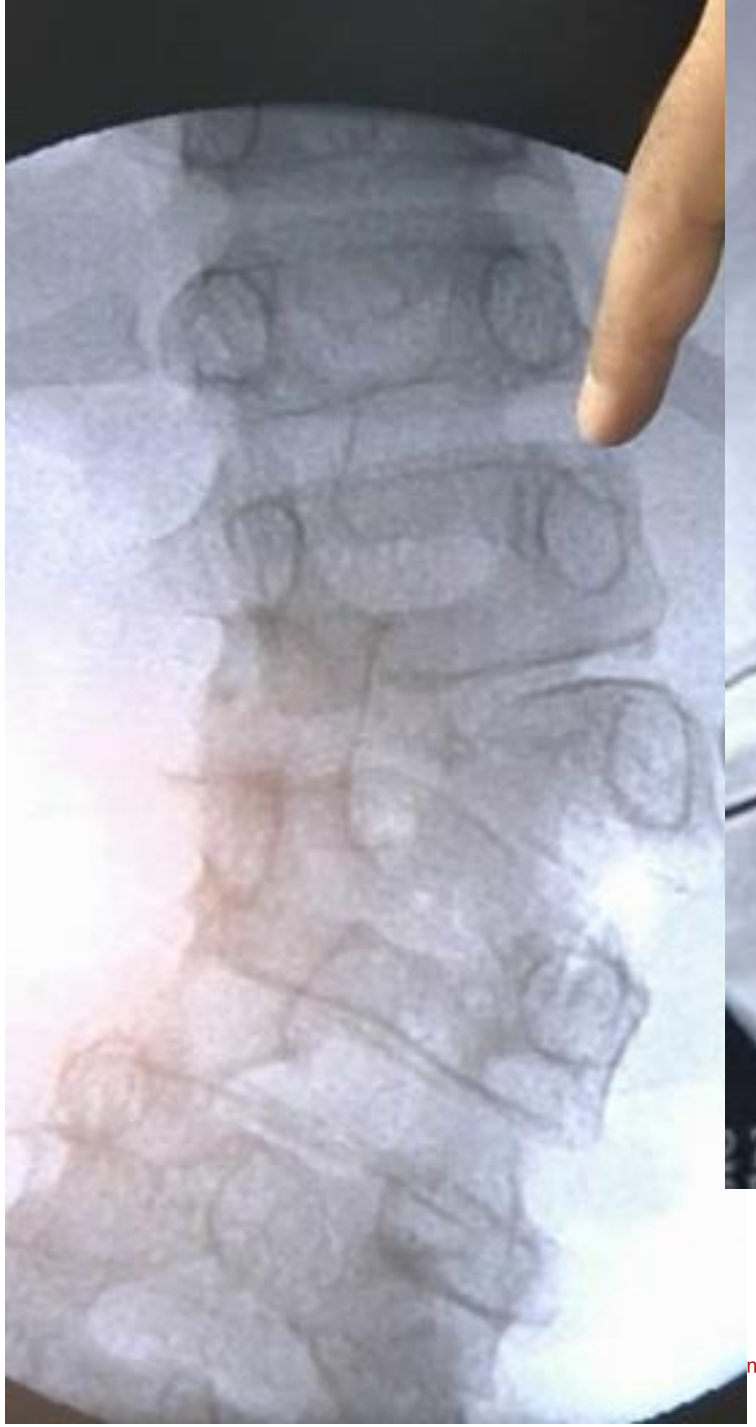

SPINE Volume 34, Number 6, pp E225–E229
©2009, Lippincott Williams & Wilkins

Three Rod Technique Facilitates Hemivertebra Wedge Excision in Young Children Through a Posterior Only Approach

Daniel Hedequist, MD, John Emans, MD, and Mark Proctor, MD

2020
WEBINAIRES

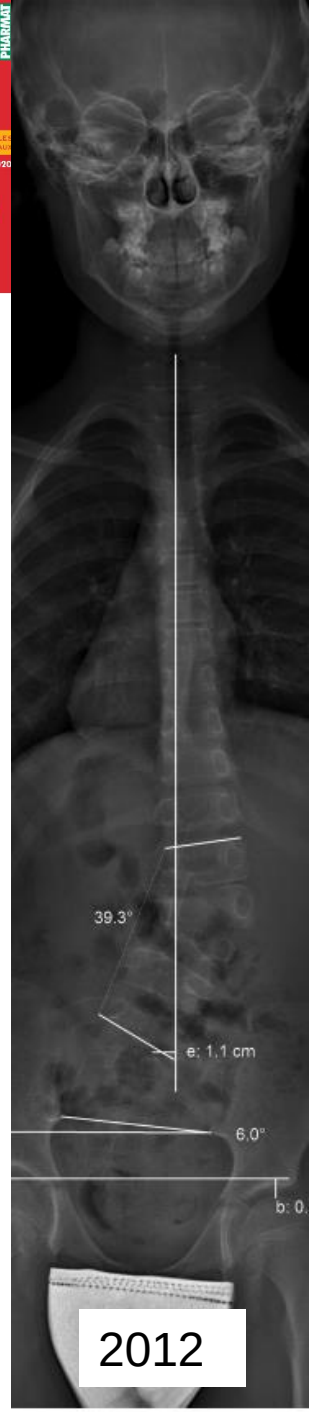
39.3°
e: 1,1 cm
6,0°
2012

2015

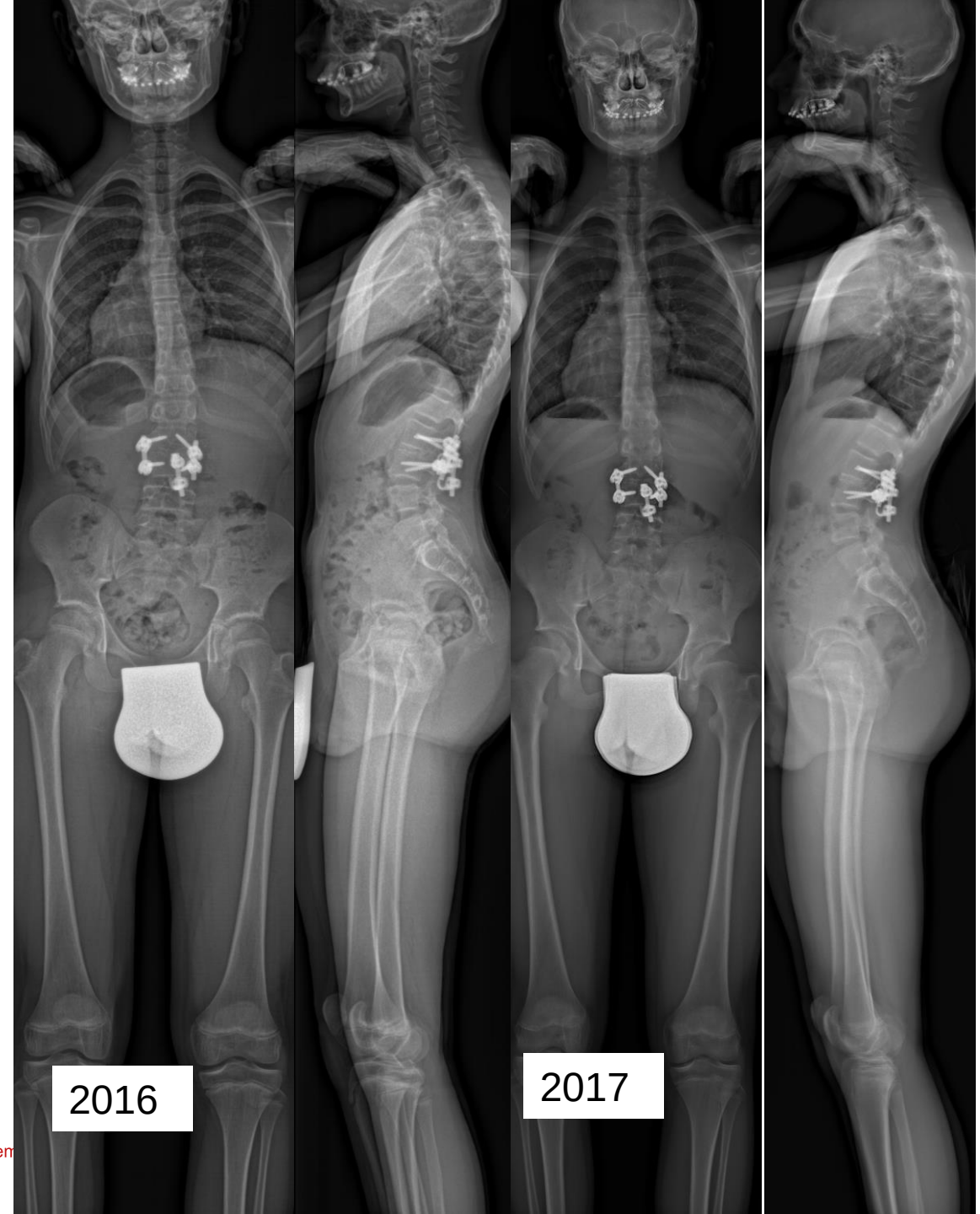
2016
2017

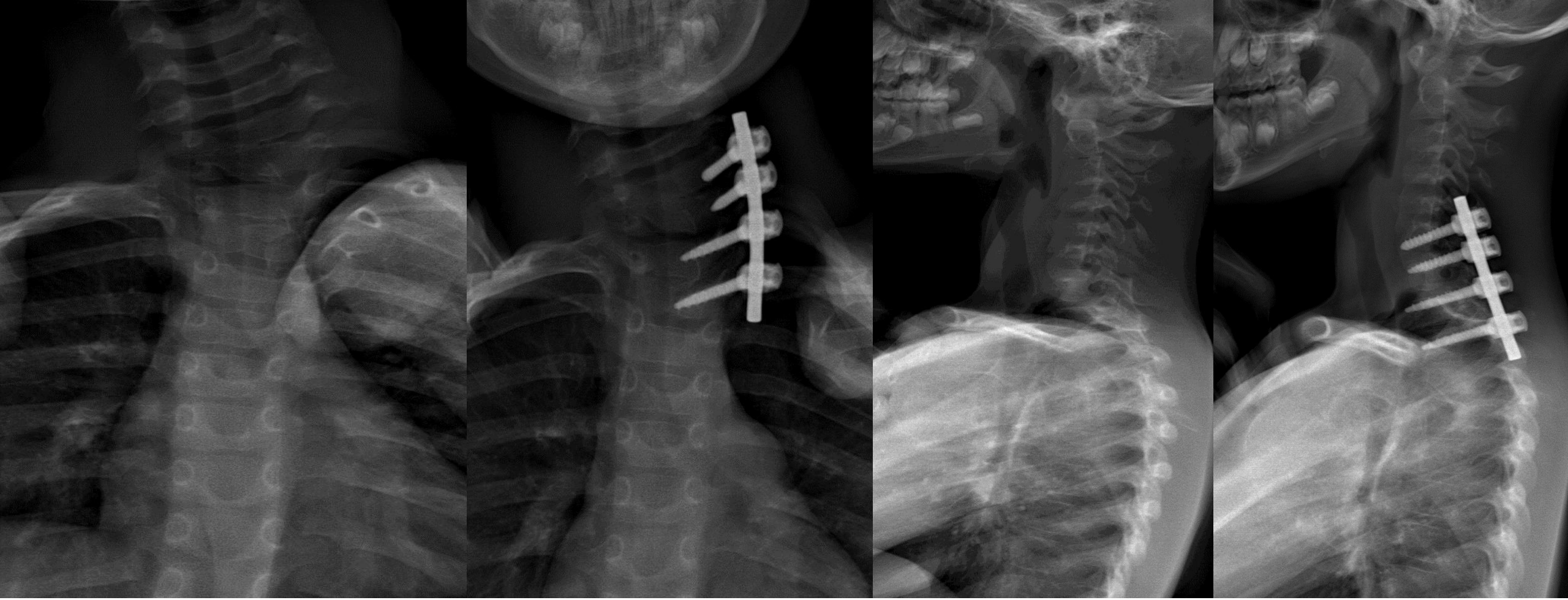

- Epiphysiodèse convexe

Tiges de croissance: Éviter la fusion précoce étendue

- Objectifs primaires
  - Réduire la déformation et son effet sur les poumons
  - Permettre une croissance du rachis thoracique

- Objectifs secondaires:
  - Taille du patient
  - Vibrequin

Tiges de croissance: classification selon

- Type de Fixation: rachidienne/iliaque/costale
- Technique d’allongement: invasive ou non

Chirurgie sans fusion

Fixation vertébrale +/- costale

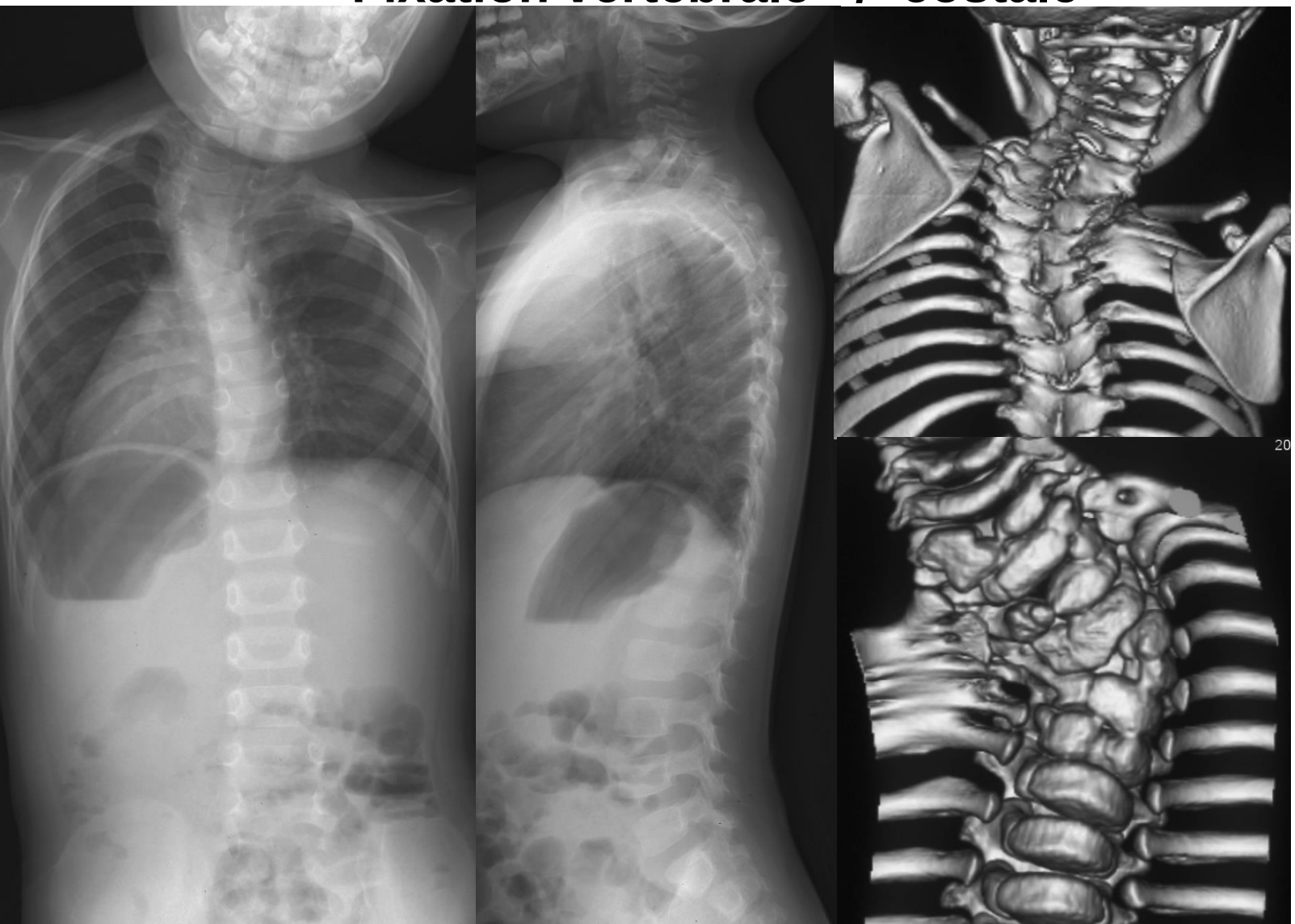

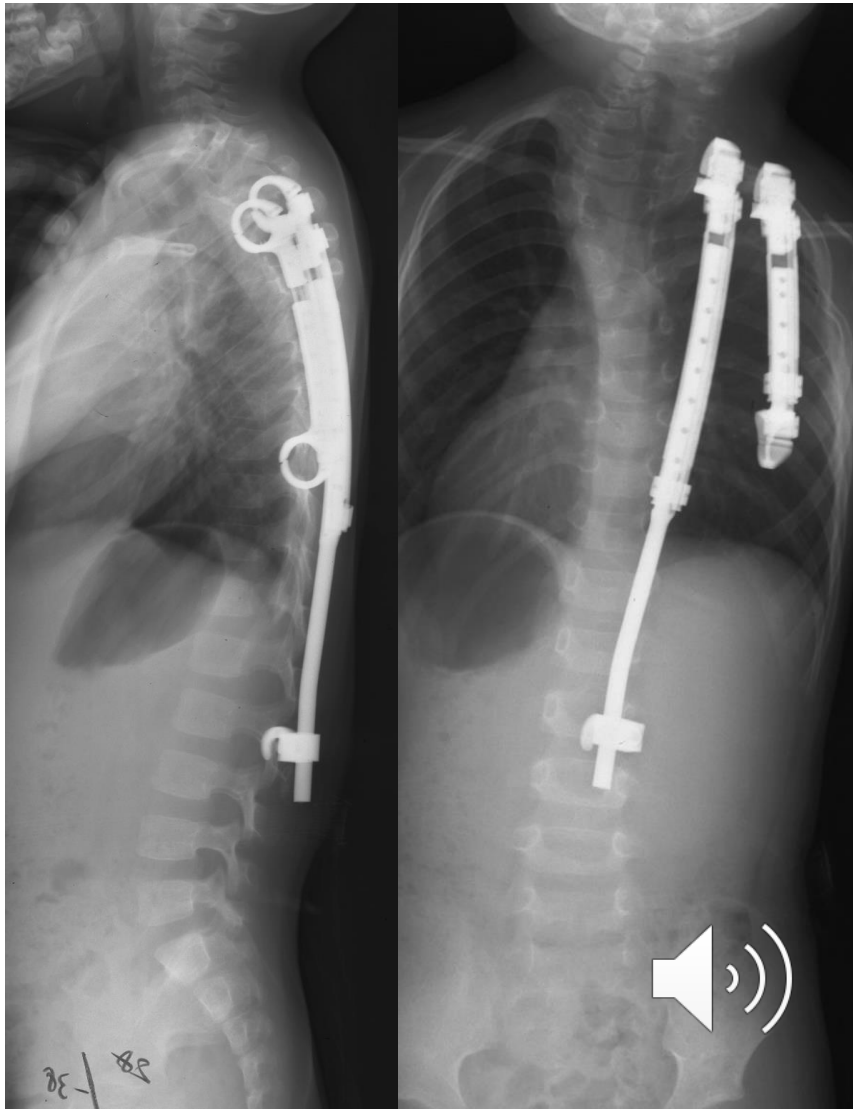

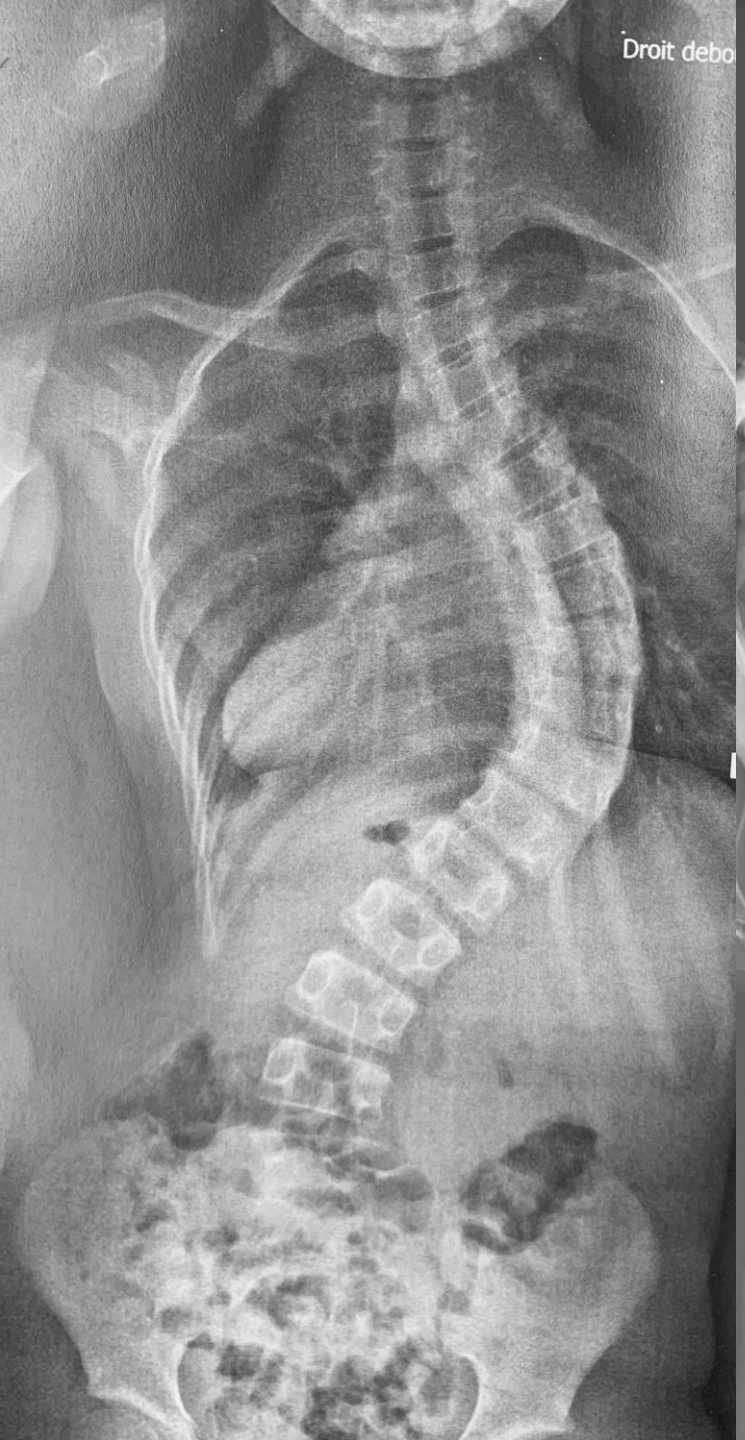

Connecteur classique

Fixation vertébral

2 ans

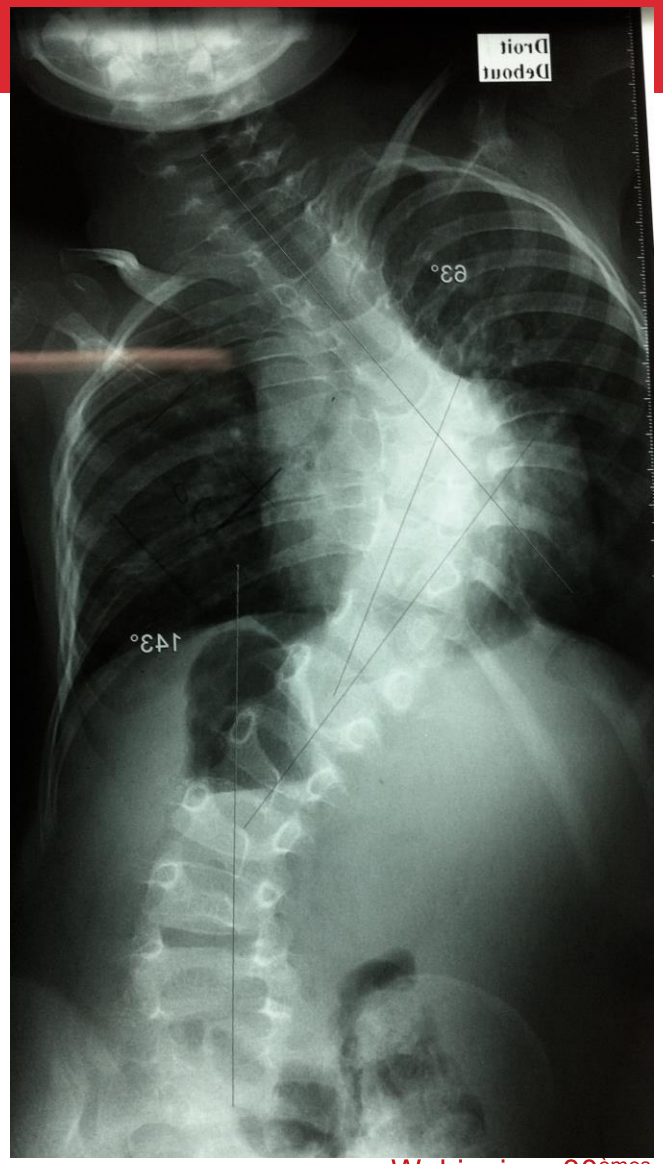

3 ans

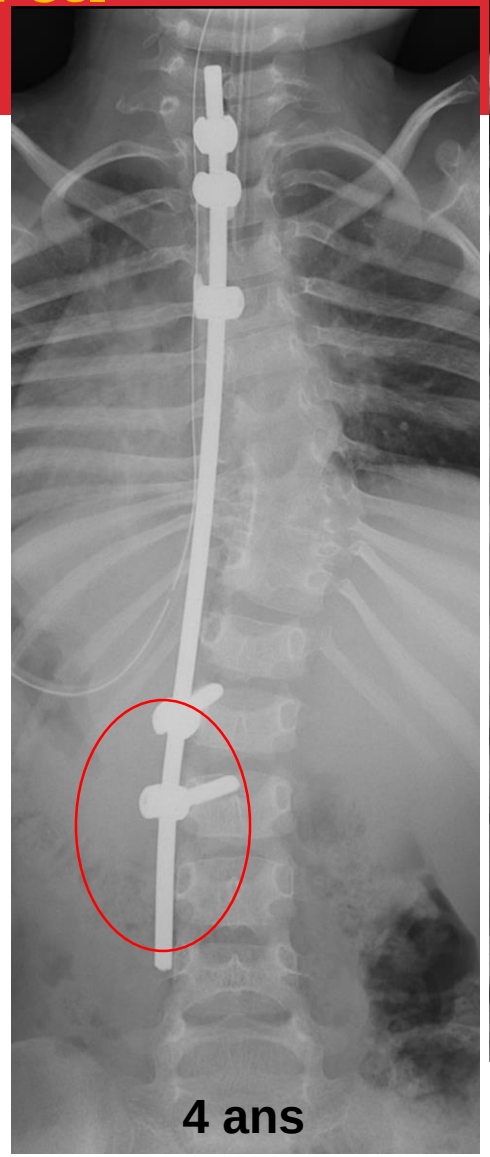

4 ans

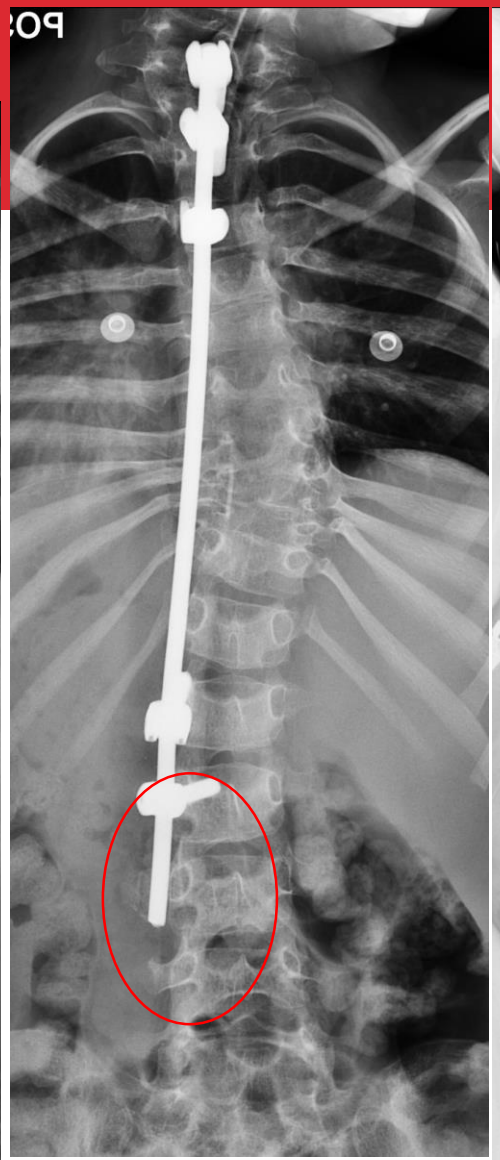

5 ans

2020
EUROPHARMAT
10e JOURNÉES NATIONALES
SUR LES DISPOSITIFS MÉDICAUX
6, 7, 8 ET 9 OCTOBRE 2020

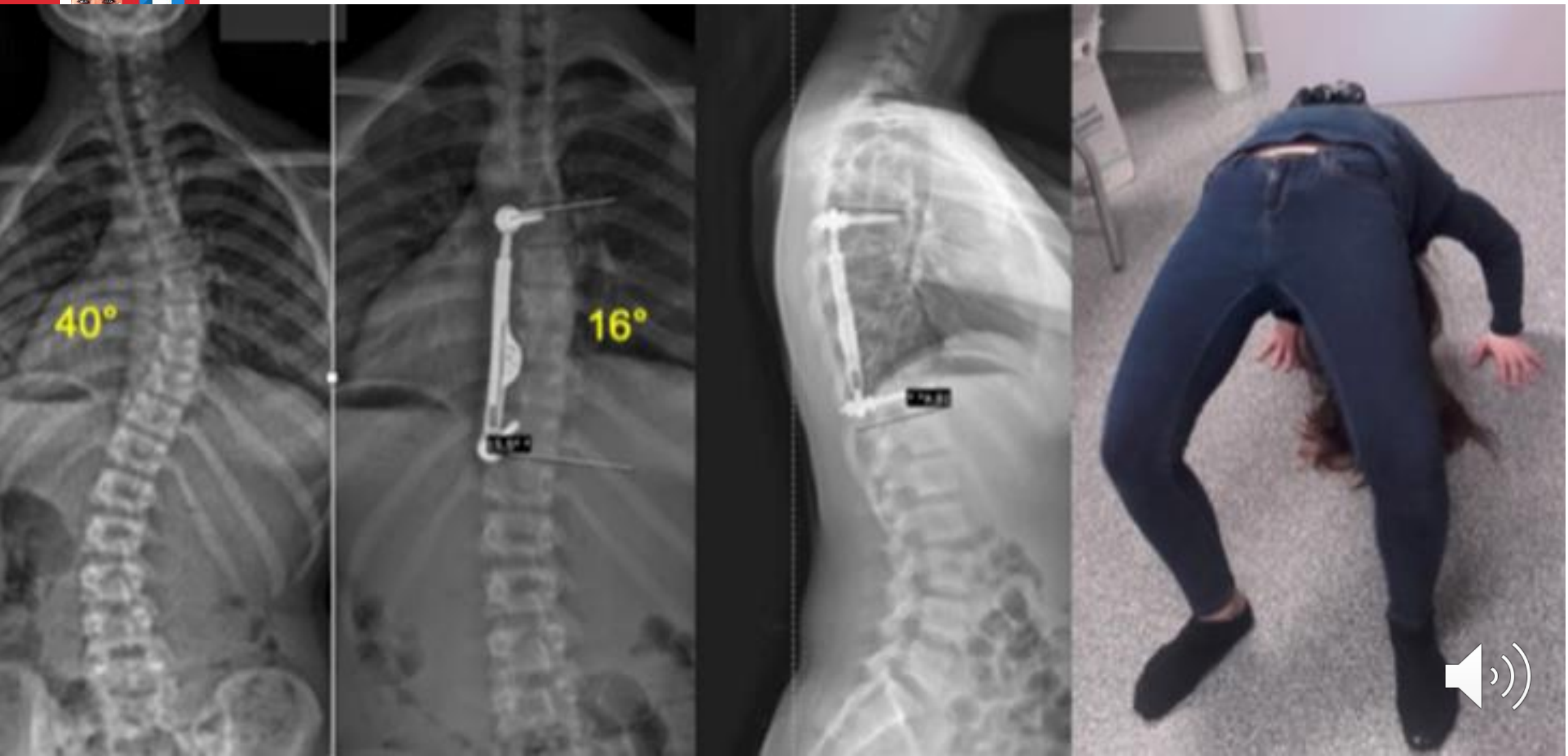
40°
16°

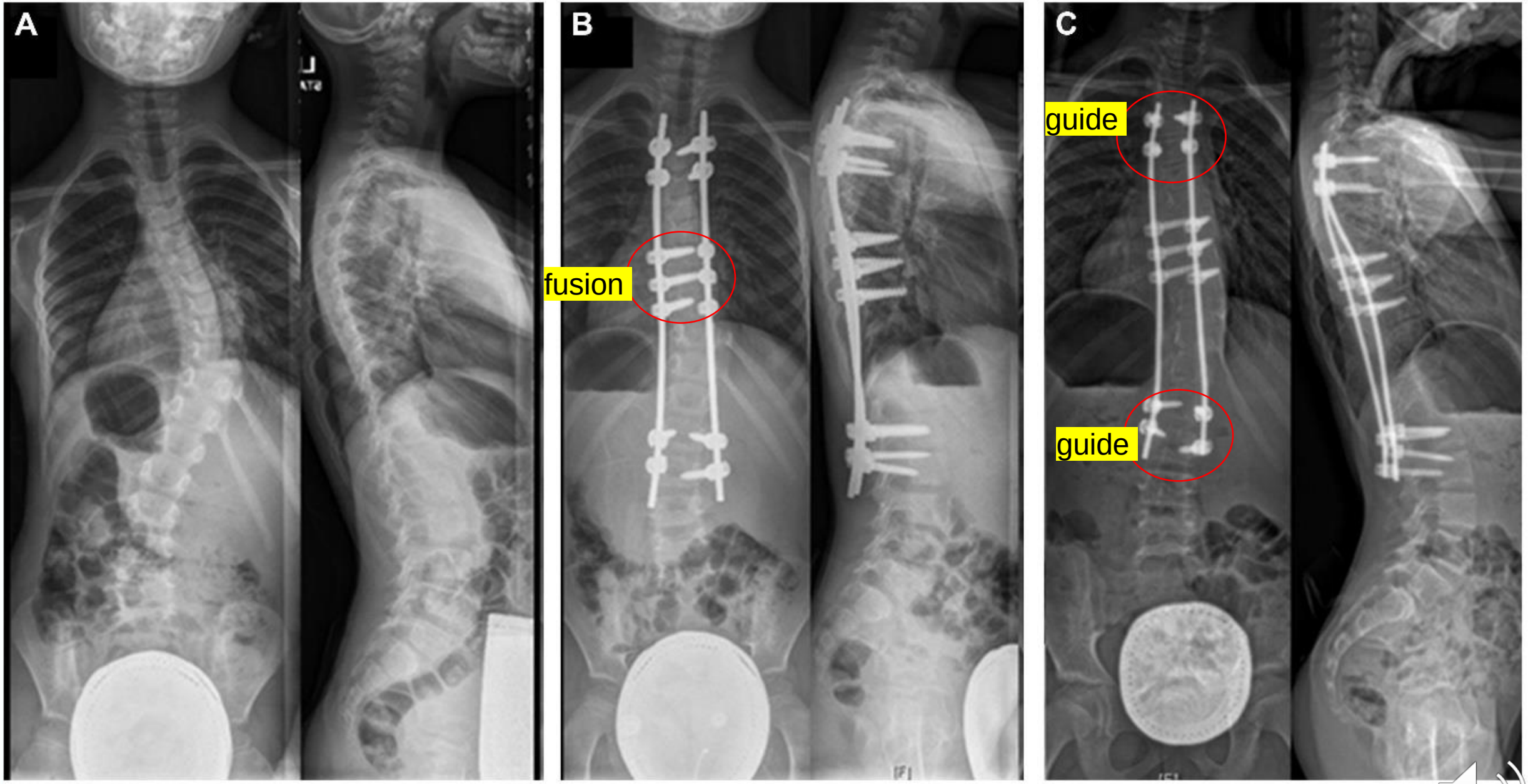

Shilla technique: fusion au sommet et guide aux extrémités

23/04/2013

28/10/2013

3/09/2014

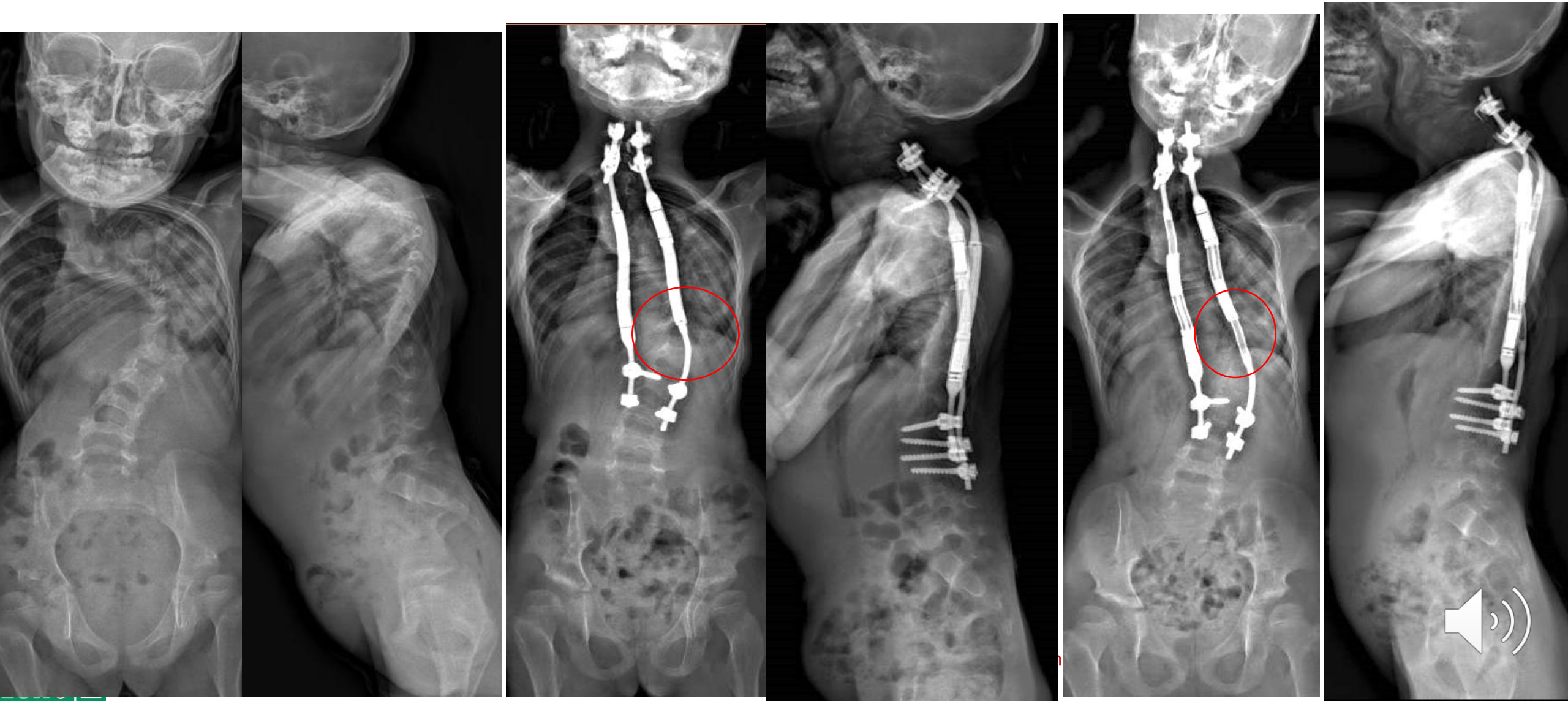

23/07/2019 16/09/2020

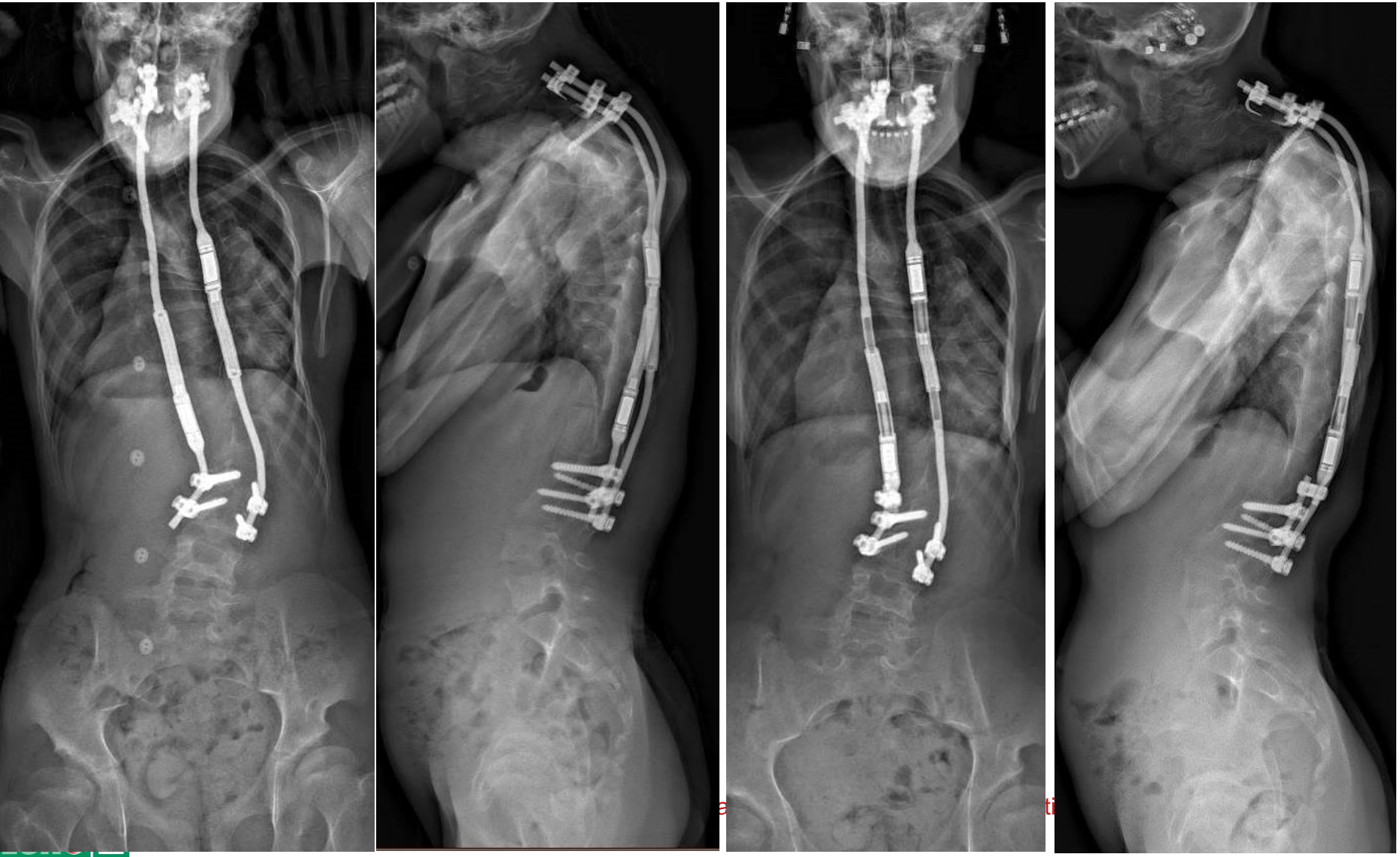

- Current situation with the technology
  - Image guided navigation
  - Robotic-assisted surgery



- General principle:

“Smart systems must palliate the deficiencies of the spine surgeon and not do only what the surgeon is already doing!”

Principe de la Navigation

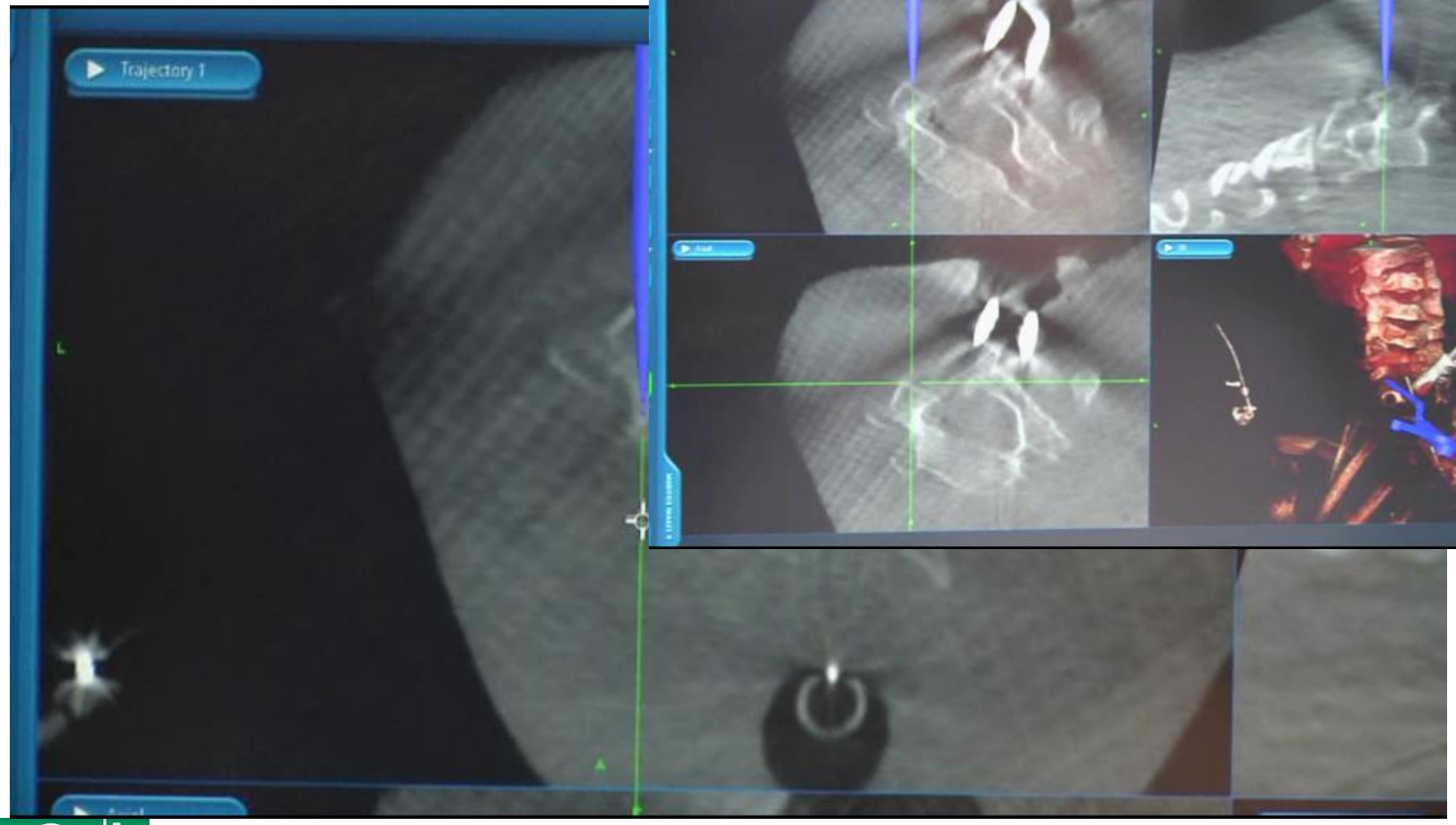

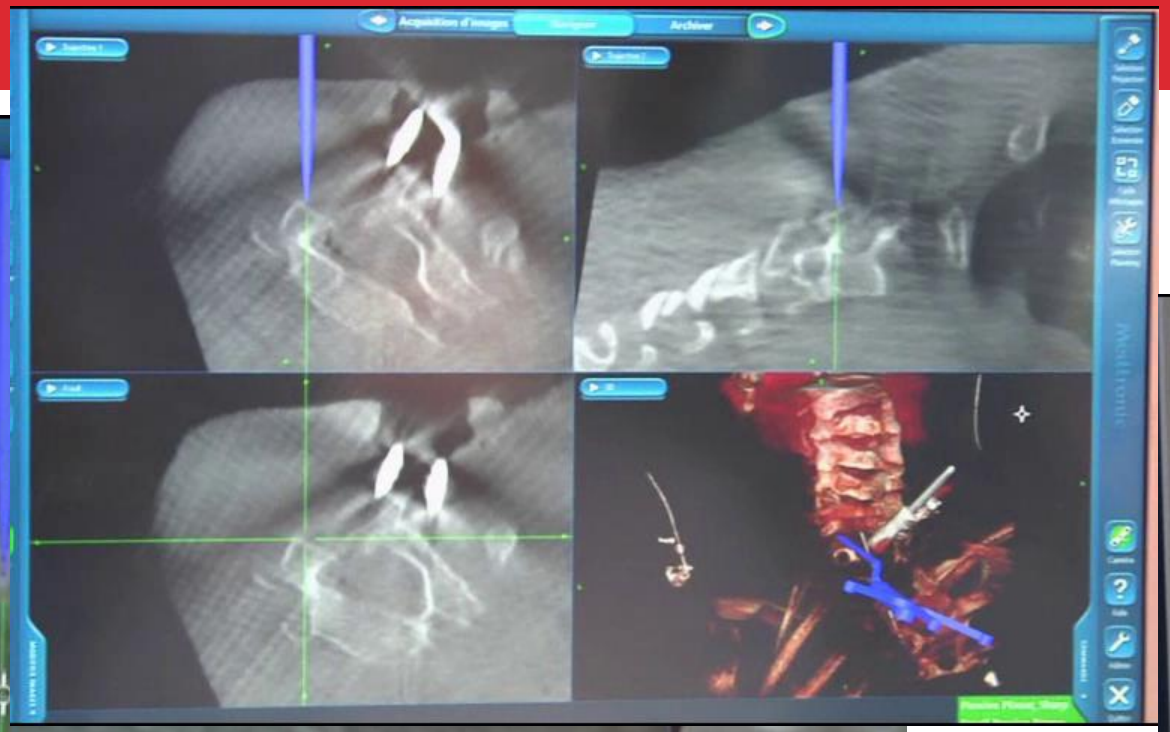

When I think about robotic-assisted spine surgery, it must respond to different challenges like:

- Physical and mental fatigu

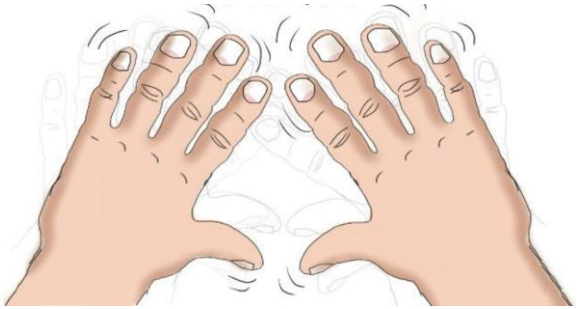

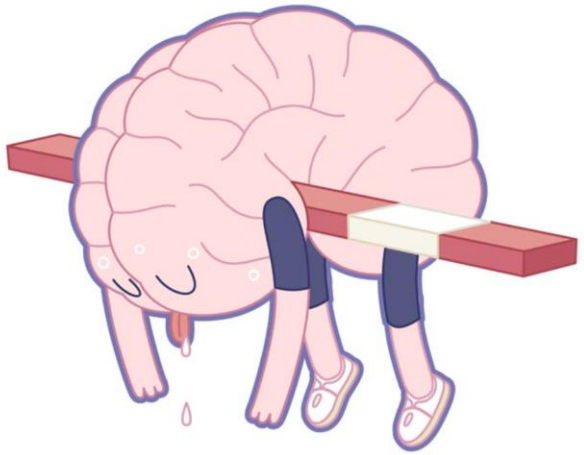

- Hand tremor



- Surgical precision

- The limits of image-guided navigation

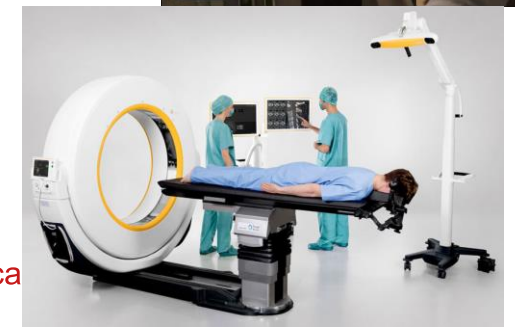

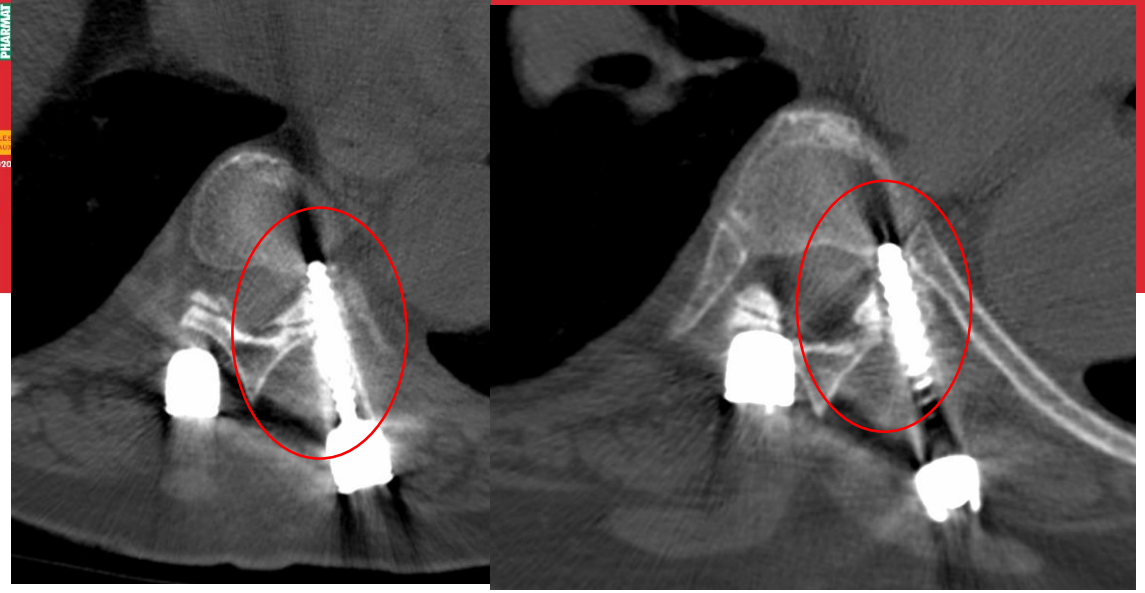

Robotic percutaneous pedicle screw insertion
Calibration problem
Wrong strategy

Always a human control behind the robot

Merci de votre attention